



September 2014

Resident *Review*

Cutting Edge Orthopaedic Information Enhancing Resident Education

From the Editor

Kristan A. Pierz, MD



Kristan A. Pierz, MD

The back to school feeling is in the air. It's the perfect time to think about what we need to learn and how to best learn it. Additionally, it's important to share knowledge and experiences with others. One of the exciting aspects about the medical profession is that things are always changing. The field of pediatric orthopaedics is no exception.

New technologies, procedures, treatment modalities, and other innovations are constantly being discovered. Keeping up with such discoveries can be quite a challenge. With life-long learning as a priority, members of the Pediatric Orthopaedic Society of North America (POSNA) are dedicated to keeping up with change. *Resident Review* is just one of the ways POSNA can help introduce residents and fellows to the world of pediatric orthopaedics, present articles and practice questions to help prepare for in-training exams, and provide useful information for career planning.

In this issue of *Resident Review*, we highlight just a few of the ways POSNA's members are advancing education, locally as well as internationally. Dr. Brian Scannell's interview with Dr. Donald Bae focuses on how residencies are implementing simulation more and more into training programs. With increasing numbers of things to learn and decreasing time to learn them, simulation offers educational opportunities to practice skills without compromising patient safety. Once mastered, such skills can be used to benefit those both near and far. Dr. John Grayhack's interview with Dr. Richard Schwend, this year's recipient of POSNA's Humanitarian Award, is an interesting piece that showcases Dr. Schwend's generous contributions to under-resourced parts of our world. Perhaps, this story will inspire some to reach beyond our borders

continued on page 2

Technology Corner: Update on Apps for Residents

By Orrin Franko, MD



Orrin Franko, MD

The number of high-quality apps available to orthopaedic residents continues to increase at a staggering rate with the current estimate at over 300 apps for iPad, iPhone, and Android. For a complete list with individual reviews, visit www.TopOrthoApps.com. In this article I will review a few recent app releases that residents and fellows will find useful for training.

Insights Orthopedics is a free comprehensive and visually stunning news and research aggregator for orthopedics. Using their specialized search engine, the app collects orthopaedic journals, videos, full-text articles, news, podcasts, images, clinical trials, and association information and presents it in a clear and functional format. The app is essentially a "flipboard for orthopaedic surgeons." A simple swipe of the keyboard quickly scrolls through the various information sources permitting continued browsing of abstracts. All articles include a link to the publisher's page and, in many instances, full access to the article if open access is available through an institutional subscription. The intuitive user interface includes the ability to bookmark resources for off-line browsing or share links via Twitter, Facebook, LinkedIn, email, and SMS. The app also includes additional features such as international journal club recommendations and an event calendar for conferences and meetings.

BoneDoc is marketed as "a serious game for surgeons" and functions as an interactive and educational orthopaedic tool for trainees. The app is organized into a list of patients that need surgery. The first case, for example, is a hip fracture that requires fixation. The surgeon must walk through every step of the operation, beginning with setting up the traction table properly. Xrays are available as the traction

continued on page 7

to help others. Additionally in this issue, Dr. Orrin Franko's Technology Corner features numerous apps that can be very useful for locating information at the tip of your fingers. Regarding career planning, you will find an article summarizing this year's match results for pediatric orthopaedics as well as a piece discussing workforce needs in the

field. For those looking to present research projects, a list of upcoming meetings and submission deadlines is also provided. Finally, no issue of *Resident Review* would be complete without some questions to test your knowledge and keep you sharp. This edition focuses on conditions affecting the pediatric hip.

Resident Review is truly here for you – the resident. We hope that you find the content both interesting and informative. Feel free to share any comments at kpierz@connecticutchildrens.org, and check out the POSNA website at www.POSNA.org. ■

Information about the Pediatric Orthopaedic Fellowship Match

By Jon Oda, MD

The results of this year's match were announced on April 11th, 2014.

- 76 applicants participated in this year's match (57 from North American programs, 19 International medical graduates)
- 44 pediatric orthopaedic fellowship programs with 71 open fellowship positions submitted rank lists.
- 60 applicants matched with one of their ranked fellowship programs. 16 applicants did not match with a fellowship program (3 North American applicants, 13 International medical graduates)
- 50% of applicants matched with their top choice program; 72% of applicants matched to one of their top three ranked programs
- A survey of applicants to the 2014 pediatric orthopaedic match (72% response rate) revealed that applicants applied to an average of 16 programs and interviewed at an average of 8.5 programs.
- A survey of fellowship directors (80% response rate) showed that an average of 13.8 interviews were offered and an average of 11.1 interviews were conducted per program.

Pediatric orthopaedic fellowships have garnered increased interest over the past several years (76 applicants in 2014, 67 in 2013, 61 in 2012) and several pediatric orthopaedic programs are considering adding additional positions in the upcoming years. Applicants to the 2015 match (for fellowships starting in 2016) may begin submitting their applications on September 2, 2014 through the SF Match Program website (www.sfmach.org). Information regarding the match process as well as a complete listing of fellowship positions can be found on both the AAOS website and the POSNA website.

Interview with Dr. Richard Schwend

By Dr. John Grayhack

Dr. Richard Schwend from Kansas City was awarded the POSNA 2014 Humanitarian award. He was kind enough to answer some questions regarding this part of his career and life when he sat down with Dr. John Grayhack.

DR. GRAYHACK: Was there a point at which you made a conscious decision to become more involved in such projects?

DR. SCHWEND: It really started at the end of medical school. I had always enjoyed travelling and applied for a fellowship which allowed me to travel with my wife to Liberia for four months at the end of medical school. This proved to be a true “dose of reality” regarding the conditions and medical care for certain populations from under-resourced regions of the world.

DR. GRAYHACK: And how did this evolve?

DR. SCHWEND: At the conclusion of medical school I had a public health service obligation. I completed a pediatric residency and was assigned to the Zuni Indian Reservation in western New Mexico for two years. There I was the medical director of the hospital and clinic and was able to work with numerous dedicated public health professionals. I had always thought I might go into orthopaedics, and in this primary care setting I had to do a lot of the orthopaedic care and trauma, which stimulated me further. In addition, I understood the difference one could make in a setting such as this. We were the first US government hospital to put in a no smoking policy. There was a good deal of backlash, but it stuck.

I really enjoyed the whole experience of being a doctor to a population and stayed on an extra year.

DR. GRAYHACK: Once you began orthopaedics, were there any opportunities through mentors who influenced this?

DR. SCHWEND: Quite definitely. Dr. John Hall was a tremendous mentor. He had travelled extensively earlier in his career to India and Africa, and told us his many stories of doing Harrington instrumentation for children in those settings. Dr. Peter Waters asked me as a fellow to accompany him to Romania after the fall of communism. Dr. Waters was so generous to pay my way, and we worked with an orphanage doing reconstructive hand surgery. I returned several times later when Dr. Waters could not go. Later, when I worked in practice with Dr. Bob Gillespie, he really encouraged me to travel, visit senior surgeons and continue this type of work. Once you get started, it’s very hard to say no, especially when you have such great mentors guiding and encouraging you.

DR. GRAYHACK: How did you develop the clinic in Ecuador?

DR. SCHWEND: In 2001 I was deployed to the Air Force as a reserve officer after 9/11. During this time I was asked to go to the Navy Hospital in Ecuador for a humanitarian mission to provide surgical care for Ecuadorian children who could not get orthopaedic surgery. Sister Annie Credido, a Catholic nun, was the local host of the trip. She has been devoting her entire life to the care of Ecuador people who are suffering from Hansen Disease. She was passionate about these children who



could not get orthopaedic care, so worked with us to set up a program with the Roberto Gilbert Children’s Hospital in Guayaquil, Ecuador. It has continued to grow from there.

DR. GRAYHACK: What aspects of this sort of work surprised you?

DR. SCHWEND: Well first, the energy and enthusiasm of both the accompanying professionals and of the local medical care. For example, a physical therapist went with us on one trip to Romania, and then went back of her own accord, staying for one year to train the local physical therapists to improve our outcomes. In Ecuador, they had a strong need for orthotics and prosthetics. Our own orthotist and prosthetist from Kansas City accompanied us, greatly improving their outcomes by working with the local brace team, developing their skills and improving their materials.

DR. GRAYHACK: How did the medical side evolve?

DR. SCHWEND: You need to learn what works and what doesn’t. The staff in Ecuador wanted us to do spine surgery but didn’t have the support systems (blood banks, ICU, imaging, sterile processing.) We laid out a plan and they gradually improved in each of these areas over the next several years, to the point where we now can do spine surgeries and have appropriate support and outcomes. A key part of the program is that our sterile

continued on page 6

Interview with Dr. Don Bae: *Surgical Simulation Training*

By Brian Scannell, MD

Q: Why do you feel that there has been a transition from residents simply gaining procedural experience in the OR to new alternative teaching methods like surgical simulation training?

A: Surgical simulation does not replace the invaluable experience obtained in the OR during residency training, but does improve skills acquisition and education by responding to a number of emerging trends, including opportunities lost with duty-hour restrictions; challenges associated with rapidly emerging technology, instrumentation, and minimally invasive techniques; and “top heavy” training programs in which operative experience is often delayed until more senior years of residency or fellowship.

Q: How does simulation training improve patient safety?

A: Simulation training improves patient safety on many levels. At the most fundamental level, by providing trainees the opportunity to acquire and practice technical skills in simulated settings, surgical

errors and suboptimal technical performance can be avoided during the care of actual patients. At higher levels, simulation training in team performance and crisis resource management allows for improved communication and efficiencies, particularly in high-stakes but uncommon clinical scenarios.

Q: What are some of the barriers to implementation of simulation at individual programs?

A: A number of barriers to implementation exist. Initiation of any simulation curriculum requires investment of resources (e.g. equipment, physical space, simulation models, and supervising personnel) which present challenges for training programs and hospitals/ institutions in an increasingly resource-scarce health care environment. In addition, though many institutions and programs have begun exciting and innovative simulation programs, little consensus has been reached amongst all stakeholders regarding the specific kind of simulation training that should be pursued within orthopedics.



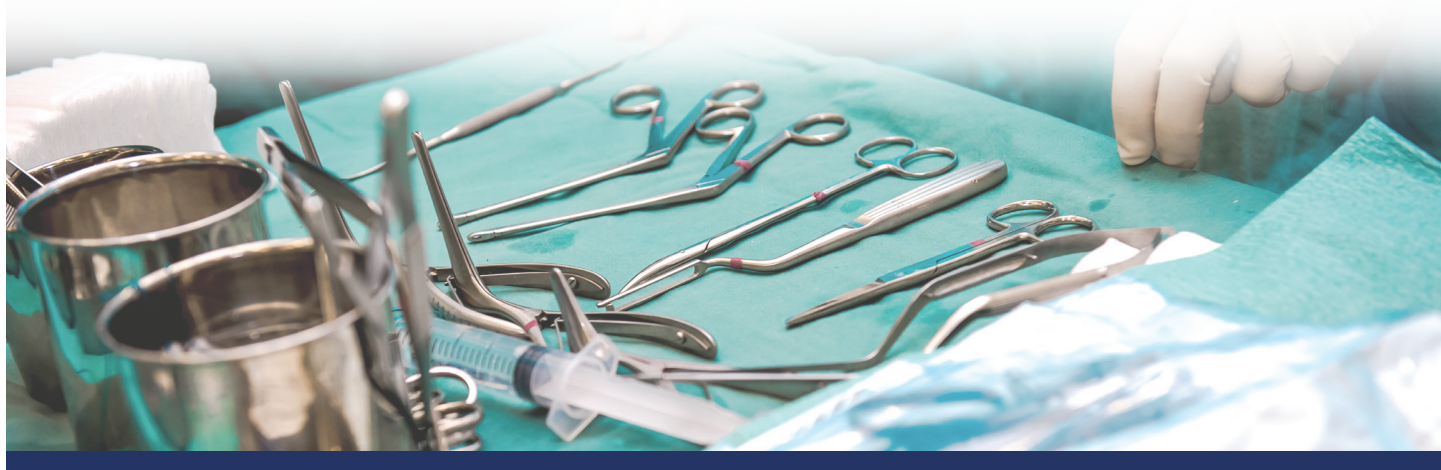Dr. Don Bae

Finally, further work needs to be done to establish validated metrics that can be followed to demonstrate how simulation improves clinical outcomes, increases patient safety, and ultimately reduces cost.

Q: The ABOS has developed recommended modules for intern surgical simulation training. Most centers have utilized these to help develop their programs. However, there is a lack of uniformity in the implementation of curriculum. How do we standardize training amongst residency programs?

A: While mandates and requirements can improve implementation -- as has been seen to some degree with how many training programs have responded to the ABOS Milestones Initiative--

continued on page 18



Interview with Dr. Jeff Sawyer

Pooya Hosseinzadeh, MD

There has been a recent increase in the number of graduates from pediatric orthopedic fellowship programs. With the increased supply of pediatric orthopedic surgeons comes a question that “Are we training too many?” We interviewed the chief of the Practice Management Committee at POSNA, Dr. Jeff Sawyer, on this issue.

1- There has been an increase in the number of applicants for pediatric orthopedic fellowships; why do you think more people are choosing pediatric orthopedics?

There are several reasons. First is that the members of POSNA surveyed chief residents a few years ago and asked them about why they chose or did not choose pediatrics. We found that orthopaedic residents were concerned about the longer work hours (call), greater medicolegal liability and decreased reimbursement in peds ortho. Since that time, POSNA and its members have made a concerted effort to show residents the positives about pediatric orthopaedics and why we get so much satisfaction from it. This as well as improved compensation packages and other factors has caused us to see an increase in the number of applicants applying and matching each year.

2- Has this increased number of pediatric orthopedic graduates affected the number of jobs available?

We have some preliminary data that shows, similar to the adult trauma programs, that as the number of fellowship graduates increases the number of job ads in major journals decreases. This is a rough surrogate as many jobs are never advertised

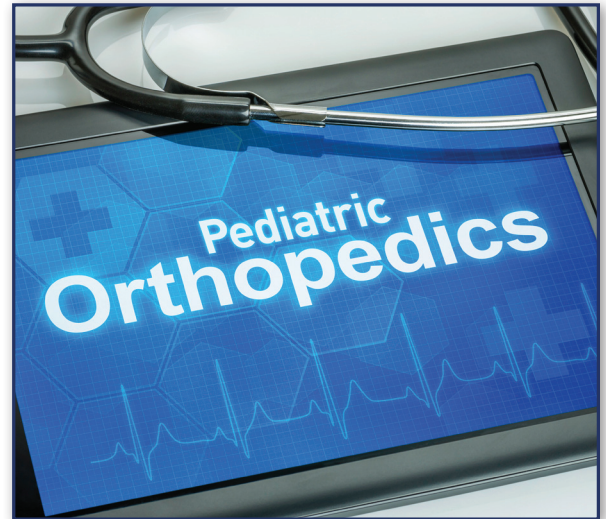
in major journals. It may be changing the types of positions available. We feel that a lot of the growth in pediatric orthopaedics may be in different areas than the classical ones such as pediatric sports, hand and trauma.

3- Do you believe we are training more pediatric orthopedic surgeons than we need?

I think it really depends on what we call a pediatric orthopedist. If we consider that person as someone who treats things that are classically treated by pediatric orthopaedists such as DDH and clubfoot then there are some concerns that there

“...POSNA and its members have made a concerted effort to show residents the positives about pediatric orthopaedics and why we get so much satisfaction from it...”

may be too many. If we expand the scope of pediatric orthopaedics to include pediatric sports, trauma, and hand surgery then the answer is maybe not. We know from the latest AAOS survey that while the number of pediatric fellows trained continues to grow that the number of orthopaedic surgeons who consider themselves to have a specialty of pediatrics has decreased



from 10.9% in 2006 to 3.9% in the most recent 2012 survey. We may need more pediatric orthopaedists if fewer children are being cared for by general orthopaedic surgeons. We are continuing to study this question, which is really being asked by all specialties in and out of orthopaedics. We will have more information coming. This will also need to be monitored closely over the next few years prospectively.

4- Recently there has been an increase in the number of pediatric orthopedic jobs available in non academic settings; could you please describe what you have found in your observations?

We do not have any data yet on this but should have some in the next year or so. From a big picture view, there is relatively small pediatric population growth predicted over the next decade which is related to a lot of factors including US GDP. If you consider that there are really a fixed number of academic positions across the US and a relatively stable rate of turnover then there will probably not be enough academic jobs for all of the graduating fellows. This may lead to growth in non-academic centers / positions.

continued on page 17

processing technician from the States has been with us on each trip to train their staff in proper sterile processing techniques. We have not had any infections since she has been involved. Two local orthopaedic surgeons have an interest and are developing the appropriate skills by working with us and visiting with our colleagues both in Central America and here.

DR. GRAYHACK: Tell us how POSNA was involved in Haiti during the period following the earthquake.

DR. SCHWEND: At that time I was on the COUR committee, with Dr. David Spiegel as Chair. A number of POSNA members responded immediately to the disaster in Haiti and were involved in many ways.



Dr. Kaye Wilkins invited me to go with him to evaluate opportunities to train a Haitian orthopaedic surgeon in pediatric orthopaedics. I was amazed at the depth and breadth of the efforts for such an extensive disaster. The group there had truly



learned to adapt to the environment and over time became more organized and could deliver care in a better fashion. One good outcome was that Dr. Francel Alexis, a Haitian orthopaedic resident decided to receive further training in Pediatric Orthopaedics, was the recipient of a POSNA COUR scholarship, and is now caring for children with a variety of musculoskeletal conditions in Port a Prince.

DR. GRAYHACK: If a resident or fellow has particular interest in this, how would one develop this more?


DR. SCHWEND: The members of POSNA have been very generous with their time and effort. There are a number of opportunities to

accompany them as trainees. Their own attendings very likely have made similar trips. The POSNA COUR Committee can help them sort this out. In addition, we recently developed a stipend through the orthopaedic section at the American Academy of Pediatrics www.aap.org/sections/ortho through which a resident or fellow can apply for funds in such a setting. I would strongly encourage them to consider this. The deadline for submission of an application is November 1, 2014.

DR. GRAYHACK: How has this affected your personal and family life?

DR. SCHWEND: My family has been remarkably supportive and actually feels it greatly benefits them. My wife has accompanied me a few times, and always encourages me to go so that I “don’t disappoint the people.” My daughter accompanied me only after I insisted she become fluent in Spanish to help me. While she’s not going into medicine, this has proven to be a true motivation in her life. There’s no question that the rewards greatly outweigh my effort.

DR. GRAYHACK: Thank you for your contributions and your time today. ☐



is adjusted to ensure that a proper reduction is obtained. Once aligned, the surgeon then moves on to the incision, as well as placement of the hardware (in this case, a sliding hip screw). Xrays are used throughout the “operation” to ensure the proper alignment and orientation of hardware, including plate position and screw length. Once finished, the surgeon receives a score for every aspect of the case, and is reimbursed appropriately. The game is very impressive due to the attention to detail that has been placed, as well as the realistic physics and challenges inherent with fixing a hip fracture.

Throw Like a Pro is not designed for residents, per se, but the quality of the app deserves mention. In response to the increasing rates of “Tommy John” surgery, Dr. Andrews created this app to help young baseball players prevent injuries and safely participate in sports. The app includes an overview of baseball throwing injuries, statistics, and general guidelines for prevention. The app then divides recommendations into Pre-Season and In-Season sections. In Pre-Season, videos are included that demonstrate how to perform 5 different stretching exercises, with instructions to complete them daily. Next, the player performs the “Throwers Ten” which includes videos of 20 more exercises that should be performed with 10 repetitions, 3-4 times/week. Lastly, there is advice for a throwing progression with a module that talks the player through the distance and number of throws to build up. The In-Season module includes a warm up with stretching (same videos), a thrower’s ten band workout (more videos), a throwing warm up and a pitching warm up. The app includes a pitch-count tool which can be modified for the patient’s age, rest days, and maximum pitches desired

(and advised). The developers estimate a 60% reduction in throwing injuries if used properly.

Orca MD is the newest app by Orca Health for patient education and engagement. Previously, their apps were called Hand Decide, Spine Decide, Shoulder Decide, etc. This new app centralizes all patient information and integrates a subscription option for annotating and emailing patients information about their condition. The overall user interface, graphics, and interactive anatomy modules are superb and allow the patient to learn about bones, tendons, and ligaments while rotating, flexing, and zooming in on the 3D anatomy images. The conditions covered for each body part are vast, and include 15-20 of the most common diagnoses. After selecting a topic, each disease includes a plethora of xray, MRI, and CT imaging with appropriate annotations demonstrating normal and pathologic conditions. Audio recordings are also included to narrate the text, and often intra-operative videos are included as well. This app is a clear stand-out that should be kept in mind for any surgeon.

Despite its catchy name and cute icon, **Bone Ninja** is neither a toy nor a game. This is a sophisticated and serious app created by the International Center for Limb Lengthening to teach pre-operative planning for limb lengthening and alignment surgery. The app is primarily used as a tool for the deformity course that they host, and I advise that anyone interested in the app either take the course or watch one of the introductory lectures. The app itself includes a library of images for practicing and learning. This includes both frontal and sagittal plane views of limbs with various angular deformities. The user can also upload any other patient

image. Once an image is selected, you enter the editing mode. The features are impressive, and include calibration and enhanced editing tools such as various select functions, linking options, the ability to free-cut the image, angular and length measurement tools and rulers, and more. It even has “hardware” icons that can be added to the images. This is a very powerful teaching tool for residents and surgeons alike.

Residents will notice an increasing trend towards social networking and communication tools for surgeons in the upcoming years. **DocSpera** is one company and app developed specifically for collaboration and case sharing among medical professionals. With an orthopaedic surgeon co-founder, it has been tailored for the proceduralist, and functions as a networking and case-sharing tool for surgeons. The app requires registration as a verified physician. Once complete, all functionality is available for free, including access to the contact list, invitations to join specific networks, the ability to upload documents and images to a personal filing cabinet, and messaging features. Some of the most useful features include the ability to create a personal network for a practice, society, or specialty interest group. Discussion threads can be initiated by any group member and are visible only to those within the group. In addition, because of its HIPAA compliant standards, specific patient information is secure through the platform and protected for public view. Overall, DocSpera is a great solution for practices or providers looking to collaborate and share information about patients and cases.

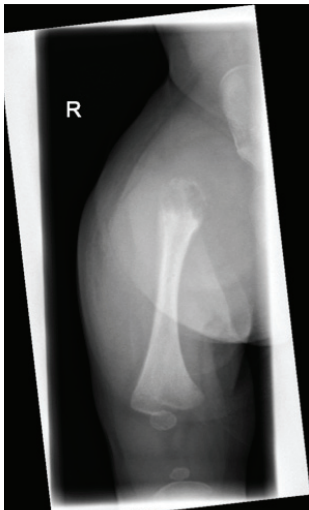
**Disclosures: Orrin Franko receives consulting fees or has an ownership interest in www.TopOrthoApps.com, DocSpera, and Insights Orthopedics.*

Hip Hip Hooray!

With the Orthopaedic In-Training Exam (OITE) just around the corner, *Resident Review* presents some questions pertaining to pediatric hip issues. Here is a way to help you prepare and test your knowledge. In addition to the questions included here, additional topics are covered in past issues of *Resident Review* that can be accessed at www.POSNA.org. Good luck!

Question 1

A two-month old baby presents with decreased motion in the right lower extremity. Mother denies any trauma. She states that the baby just started to act fussy and irritable, especially during diaper changes.



X-ray (Figure) is obtained and you are awaiting lab results. This child will benefit most from the following next step:

- A) Complete a skeletal survey and contact child protective services while preparing to cast the child
- B) Obtain an MRI of the femur
- C) Consult an orthopaedist who specializes in bone tumors, and transfer to a facility with such specialists if necessary

- D) Obtain ultrasound of hips and prepare for urgent surgical aspiration, irrigation and debridement
- E) Obtain a bone scan

Preferred answer: D

Discussion: This baby has osteomyelitis of the femur with a septic right hip resulting in subluxation of the joint. Transphyseal vessels predispose neonates to septic arthritis. Infection of the joint typically occurs via hematogenous invasion, but can occur via extension from an adjacent site or direct inoculation. There is a correlation between younger age at presentation as well as delay in treatment with severity of residual hip deformity. Ultrasounds can typically be obtained quickly and without sedation to confirm presence of effusion. Early treatment includes parenteral antibiotics and surgical drainage. An MRI may be useful to understand residual deformity or assess response to treatment but is unlikely to change initial management. Residual deformity of the epiphysis, physis, and metaphysis may require surgeries to address deformity, persistent hip subluxation, leg length difference and abductor insufficiency.

References:

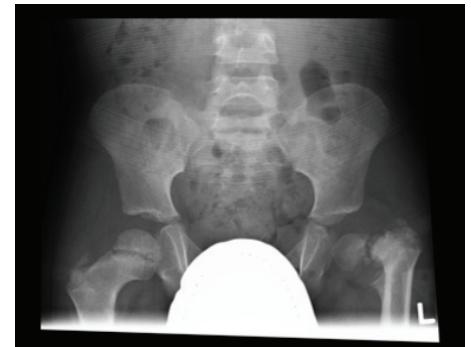1. Choi IH, Pizzutillo PD, Bowen JR, et al: Sequelae and reconstruction after septic arthritis of the hip in infants. *J Bone Joint Surg Am.* 1990 Sep;72(8):1150-65.
2. Samora JF, Klingele K: Septic arthritis of the neonatal hip: acute management and late reconstruction. *J Am Acad Orthop Surg.* 2013 Oct;21(10):632-41.
3. Bennett OM, Namnyak SS: Acute septic arthritis of the hip joint in infancy and childhood. *Clin Orthop Relat Res.* 1992 Aug;(281):123-32.

Question 2

A 4-year-old boy presents with wide based gait, out-toeing, and limp. An Xray (figure) was obtained. The best treatment recommendation is:

- A) In situ screw fixation bilateral proximal femurs
- B) In situ screw fixation left proximal femur
- C) Urgent open reduction internal fixation of left proximal femur
- D) Valgus osteotomy left proximal femur
- E) Bilateral valgus osteotomies

Preferred answer: D) valgus osteotomy left proximal femur.



Discussion: This Xray is consistent with congenital coxa vara. The Hilgenreiner-epiphyseal angle measures 12 degrees on the right and 70 degrees on the left. Spontaneous improvement of this deformity can be seen in patients with HE angle less than 40, whereas those with HE angles greater than 60 usually require surgery. For those with HE angles between 40 and 60 degrees, observation may be recommended initially to see if spontaneous improvement occurs; however, many of these will have progressive deformity for which osteotomy may be indicated. Surgical correction to a

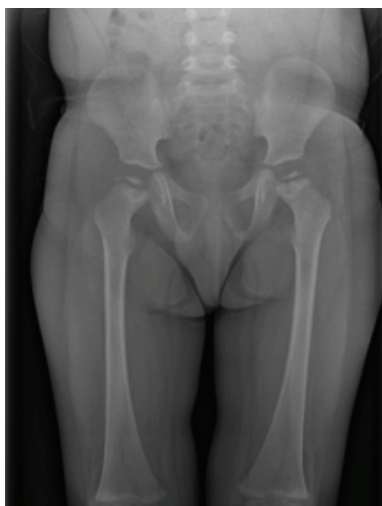HE < 38 degrees has been shown to prevent recurrence of deformity in 95% of cases.

References:

1. Carroll K, Coleman S, Stevens PM: Coxa vara: surgical outcomes of valgus osteotomies. J Pediatr Orthop. 1997 Mar-Apr;17(2):220-4.
2. Sabharwal S, Mittal R, Cox G: Percutaneous triplanar femoral osteotomy correction for developmental coxa vara: a new technique. J Pediatr Orthop. 2005 Jan-Feb;25(1):28-33

Question 3

2 year 7 month old Hispanic male presents with complaints of a few months of abnormal gait and limping. He has not had any injury, and has had no systemic signs of infection or illness. His mother says that one or two times a week he seems to have an exacerbation of his limp, and complains of bilateral knee pain. He does not waken at night. He is otherwise healthy, gaining weight and has been developmentally normal. He is in the 50th percentile for height and weight.



On examination he does not have a notable limp today, has good muscle strength, good balance and tone.

He has excellent muscle strength throughout, and negative Gowers sign.

An AP Pelvis radiograph is shown.

Based on the presentation and imaging, the most likely diagnosis is:

- 1) Sickle cell disease
- 2) Spondyloepiphyseal dysplasia
- 3) Multiple epiphyseal dysplasia
- 4) Meyer dysplasia
- 5) Hypothyroidism

Preferred Response: 4

Discussion: The presence of bilateral Perthes like changes in children less than 4 years old should prompt an assessment for a systemic disease like hypothyroidism or a skeletal dysplasia. With normal growth plates, normal height and normal development, spondyloepiphyseal dysplasia, multiple epiphyseal dysplasia and hypothyroidism are unlikely. If there is a question a skeletal survey to look for other epiphyseal abnormalities can rule out the dysplasias, and thyroid function studies can eliminate hypothyroidism as a cause. Sickle cell disease can produce bilateral proximal femoral osteonecrosis, but not typically in patients this young, and is often asymmetric, and is most common in blacks.

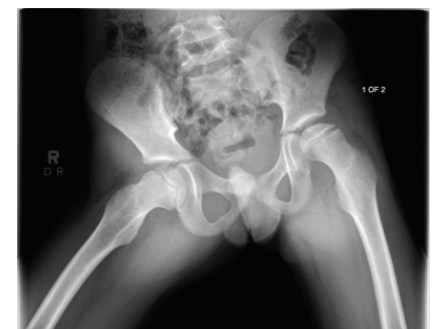
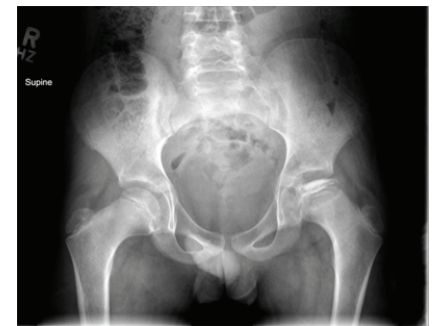References:

1. Rowe et al described Meyer dysplasia in 17 of 578 children with Perthes or Perthes like hip conditions in an Asian patient population. The average age was 2.5 years. The dysplasia is manifest as delayed, irregular ossification of proximal femoral epiphysis. Meyer described the entity as being caused by dysplasia instead of necrosis. It typically resolves with growth in 2-4 years and no treatment is indicated. 60% are bilateral.
2. Rowe SM, et al. Dysplasia epiphysealis capitis femoris: Meyer dysplasia. J Pediatr Ortho 2005;25:18-21.

3. Weinstein S. Legg-Calve-Perthes Disease. Chapter 24, pg 1138. In Lovell and Winter's Pediatric Orthopaedics. 7th edition, Lippincott Williams Wilkins, Philadelphia 2014

Question 4

A 7 year old male presents with recent onset groin pain and a limp. He is small for his age and takes medications for ADHD. Examination shows a hip limp, limited abduction on the left side. AP pelvis and frog lateral pelvis radiographs are shown.



If operative containment treatment with a femoral osteotomy after regaining hip abduction range of motion is undertaken, what principle should be followed when executing the operation?

1. Varus osteotomy should reduce the neck shaft angle to 100 degrees
2. Reduce the articulo-trochanteric distance to zero
3. Varus correction should be limited to 10 to 15 degrees

continued on page 10

- The shaft should be translated laterally to correct the mechanical axis
- Trochanteric epiphyseodesis should always be performed

Preferred response : 3

Discussion: Excessive varus correction may contribute to permanent limb length inequality, abductor weakness and permanent limping. Kim et al recommended only 10-15 degrees of varus correction in a large long term study of the Perthes Study Group.

Reduction of the articulo-trochanteric distance diminishes the lever arm for abductor muscle function and contributes to weakness. For varus osteotomy of the proximal femur, medicalization of the shaft restores mechanical axis alignment. Some authors recommend trochanteric epiphyseodesis (or apophyseodesis), but this is not universally accepted.

References:

- Kim, H. Legg-Calve-Perthes Disease. In Tachdjian's Pediatric Orthopaedics. 5th edition
- Chapter 17, pg 621. Elsevier, Philadelphia, 2014.

Question 5

A 3-year-old male presents to the ED with a history of tripping and falling after a twisting mechanism. It is evening and the patient has inability to walk, pain with range of motion of the hip, and, on the stretcher, his leg is held flexed and adducted. He presented to the ED in the evening with inability to walk, pain with ROM of his hip, and on the gurney his leg was held flexed and adducted. He denies any other injuries.

An AP femur is shown below (Figure A). What would be the next step in the management of this patient?

- Admit for observation and nonsteroidal anti-inflammatory medications
- Urgent hip ultrasound
- Admit for observation, IV antibiotics, and MRI of his hip and pelvis tomorrow
- Urgent closed reduction

Answer – D

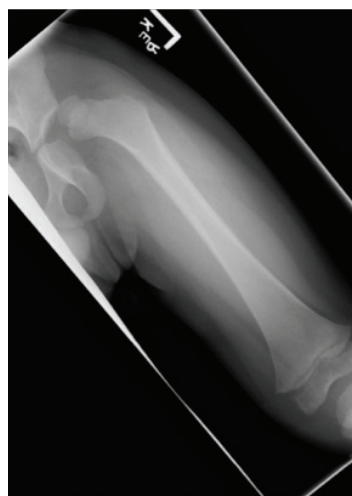

Figure A

Discussion: This patient has a hip dislocation and should be taken emergently to the operating room for a closed reduction of his hip joint. A prolonged time to hip reduction has been correlated with an increased risk of avascular necrosis of the femoral head. Intraoperatively, the surgeon should be confident of a concentric reduction, as osteochondral fractures or soft tissue interposition can occur; post-reduction CT or MRI can be useful if there is any question of occult fracture or joint space widening. Osteonecrosis has been shown to manifest up to two years after the dislocation event, so children should be monitored for several years.

The aforementioned patient

underwent emergent hip closed reduction; postreduction images revealed a concentric reduction with smooth range of motion and no other fractures noted. He was immobilized and kept nonweightbearing for 6 weeks. When talking with the family, what would be the best estimation of this patient's risk of osteonecrosis?

- 10%
- 33%
- 50%
- 75%

Answer – A

Discussion: The incidence of osteonecrosis after an isolated hip dislocation has been reported to be between 3 and 15%. Other associated injuries may increase the incidence of osteonecrosis.

- Mehlman CT, Hubbard GW, Crawford AH, et al. Traumatic hip dislocation in children: long term followup of 42 patients. *Clin Orthop Relat Res.* 2000; 376:68-79.
- Gartland JJ, Benner JH. Traumatic dislocations in the lower extremity in children. *Orthop Clin North Am.* 1976; 7:687.
- Herrera-Soto JA, Price CT. Traumatic hip dislocations in children and adolescents: pitfalls and complications. *J Am Acad Orthop Surg.* 2009; 17:15-21.

Question 6

AG is a 28 month old female who was being carried by her uncle when he tripped and fell on her. She presents to the emergency department with left proximal femur pain and deformity.

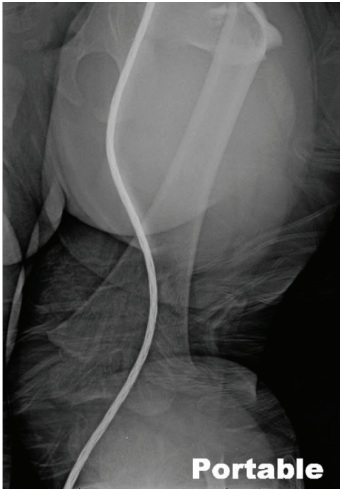

Figure A

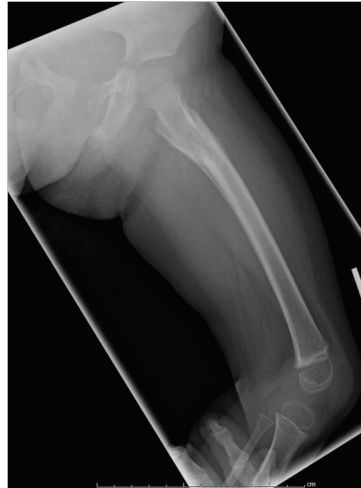

Figure D

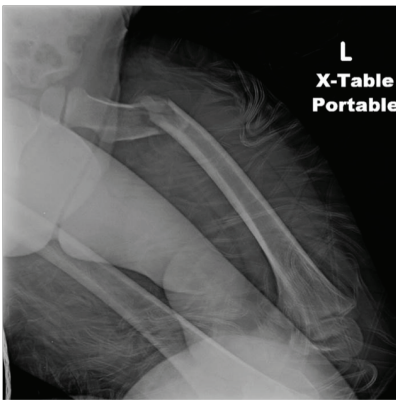


Figure B

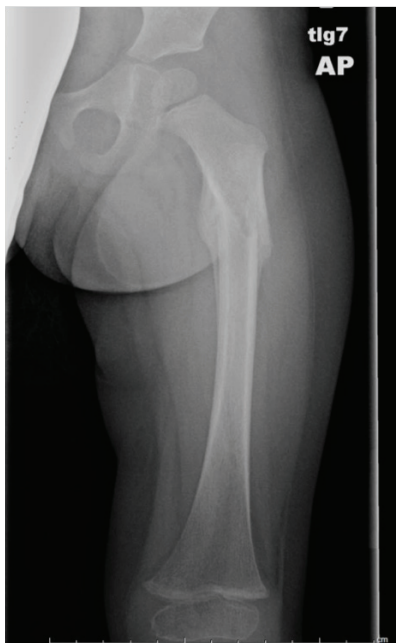


Figure C

Xrays of her left femur are above (figure A-B). She was taken to the operating room for immediate spica casting of her fracture. In the operating room, her left leg should be positioned in:

- extension, abduction, and internal rotation
- flexion, adduction, and internal rotation
- flexion, abduction, and external rotation
- extension, abduction, and external rotation

Answer – C

Discussion: The proximal fragment in subtrochanteric femur fractures in children tend to fall into flexion due to pull of the iliopsoas muscle, abduction due to the hip abductors, and lateral rotation due to the pull of the short external rotators of the hip. In order to accommodate for these deforming forces and prevent procurvatum and varus, one would try and position the distal fragment in flexion, abduction and external rotation. (answer C). Her 6 week postop xrays show mild varus and procurvatum (figure C-D), but at her age one would anticipate this to remodel rapidly. While spica casting is a viable option in the younger age group, it is more

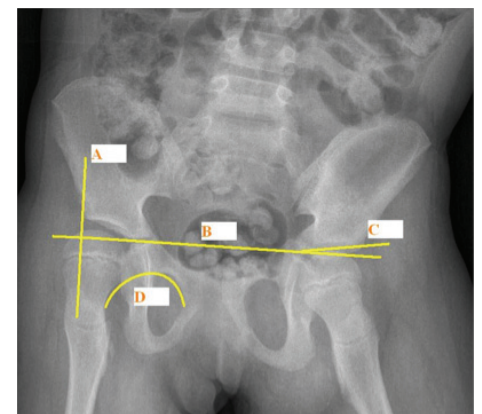
challenging to maintain an adequate reduction in older children, and many surgeons advocate titanium elastic nails, or ORIF for these fractures.

References:

- Riccio, AI, Wilson PL, Wimberly RL. Lower Extremity Injuries. In: Herring JA. Tachdjian's Pediatric Orthopaedics, 5th ed. Philadelphia, PA: Elsevier, Inc., 2014: 1401.
- Pombo MW, Shilt JS. The definition and treatment of pediatric subtrochanteric femur fractures with titanium elastic nails. J Pediatr Orthop. 2006; 26: 364-370.
- Parikh SN, Nathan ST, Priola MJ, Eismann EA. Elastic nailing for pediatric subtrochanteric and supracondylar femur fractures. Clin Orthop Relat Res. 2014; 472:2735-44.
- Li Y, Heyworth BE, Glotzbecker M, et al. Comparison of titanium elastic nail and plate fixation of pediatric subtrochanteric femur fractures. J Pediatr Orthop. 2013;33:232-238.

Question 7

In evaluating dysplastic hips, the migration of the femoral head is determined using Perkins and Hilgenreiner's lines. On the radiograph shown below, these two lines are ___ and ___, respectively.



continued on page 12

- A. C and B
- B. B and A
- C. D and A
- D. A and B
- E. A and C

Answer: D

Discussion: On the radiograph shown above, Perkins line is A, Hilgenreiner's line is B, the acetabular index is C, and Shenton's line is D. Perkins line is used in the assessment of any type of hip dysplasia. It is the radiographic line drawn perpendicular to Hilgenreiner's line and intersects the most lateral aspect of the acetabular roof. In the normal hip, the femoral head should be medial to Perkins line. The femoral head may be lateral to Perkins line in the setting of a hip subluxation or dislocation.

References:

1. Guille JT, Pizzutillo PD, MacEwen GD. Development dysplasia of the hip from birth to six months. *J Am Acad Orthop Surg.* 2000 Jul-Aug;8(4):232-42.
2. Weinstein SL, Mubarak SJ, Wenger DR. Developmental hip dysplasia and dislocation: Part I. *Instr Course Lect.* 2004;53:523-30.

Question 8

The forces which contribute to subluxation or dislocation of the hip in a child with cerebral palsy include all of the components below EXCEPT:

- A. Acetabular dysplasia
- B. Excessive femoral anteversion
- C. Spasticity of the adductors and iliopsoas
- D. Valgus of the femoral neck
- E. Spasticity of the abductors

Answer: E

Discussion: Progressive deformity of the hip in cerebral palsy is

multifactorial and includes muscle imbalance, retained primitive reflexes, abnormal positioning, and pelvic obliquity. These altered forces across the hip lead to bony deformities, including acetabular dysplasia, excessive femoral anteversion, and increased neck-shaft angle. The neck-shaft angle in children with cerebral palsy has been shown to increase with age, and anteversion, which normally decreases with age, does not change in children with cerebral palsy. The gluteus muscles are often weak in these children.

References:

1. Miller F, Browne E. *Cerebral Palsy.* Springer Science & Business Media. 2005. p. 524
2. Hoffer MM. Management of the hip in cerebral palsy. *J Bone Joint Surg Am.* 1986 Apr 68(4): 629-31.

Question 9

The most common long-term finding after in situ pinning for a stable slipped capital femoral epiphysis is the presence of:

- 1) avascular necrosis.
- 2) normal proximal femoral anatomy.
- 3) femoroacetabular impingement.
- 4) a leg length discrepancy.
- 5) painful hardware.

Preferred Response: 3

Discussion: In situ pinning for stable slipped capital femoral epiphysis remains the standard of care. However, there has been a recent increase in interest in the long-term implications of the altered proximal femoral anatomy associated with SCFEs. By definition, the slip of the head in the posterior-inferior direction alters the normal proximal femoral anatomy and creates a

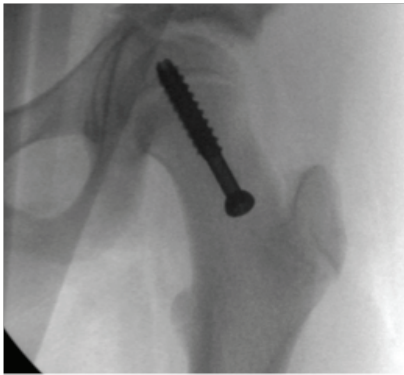
prominence of the anterior-superior metaphysis. This metaphyseal prominence can produce femoroacetabular impingement. Radiographic evidence of FAI is more common in more severe slips, but also occurs in at least 1/3 of mild slips. By comparison, the rates of AVN, leg length discrepancy, and painful hardware requiring intervention are extremely small.

References:

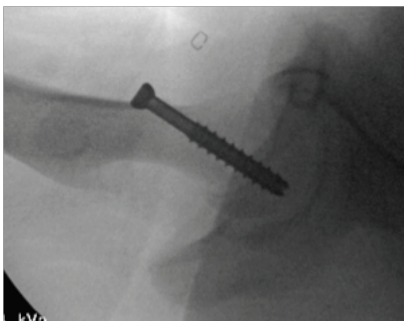1. Murgier J, de Gauzy JS, Jabbour FC, Iniguez XB, Cavaignac E, Pailhé R, Accadbled F. Long-term Evolution of Slipped Capital Femoral Epiphysis Treated by in Situ Fixation: A 26 Years Follow-up of 11 Hips. *Orthop Rev (Pavia).* 2014 Jun 3;6(2):5335.
2. Millis MB, Novais EN. In situ fixation for slipped capital femoral epiphysis: perspectives in 2011. *J Bone Joint Surg Am.* 2011 May;93 Suppl 2:46-51.
3. Fraitzl CR, Käfer W, Nelitz M, Reichel H. Radiological evidence of femoroacetabular impingement in mild slipped capital femoral epiphysis: a mean follow-up of 14.4 years after pinning in situ. *J Bone Joint Surg Br.* 2007 Dec;89(12):1592-6.
4. Dodds MK, McCormack D, Mulhall KJ. Femoroacetabular impingement after slipped capital femoral epiphysis: does slip severity predict clinical symptoms? *J Pediatr Orthop.* 2009 Sep;29(6):535-9.

Question 10

The in situ pinning technique depicted in Figures 1a and 1b increases the risk of all of the following EXCEPT:



1a



1b

- 1) limitation of postoperative hip flexion.
- 2) hip pain due to screw head impingement.
- 3) labral tearing..
- 4) plowing of the screw head through the soft metaphyseal bone of the proximal femur.
- 5) avascular necrosis.

Preferred Response: 5

Discussion: The images depict in situ pinning with the screw placed on a trajectory that is roughly perpendicular to the proximal femoral physis, but with the starting point proximal to the intertrochanteric line. Placing screws using a more proximal and anterior starting point on the femoral neck, in order to achieve a perpendicular trajectory, locates the screw head closer to the acetabulum. A screw placed in this location risks both plowing through the soft metaphyseal bone of the femoral neck, and impingement of the screw head on the acetabulum or labrum. This impingement may

limit hip flexion or lead to painful tearing of the labrum. Though it is biomechanically correct that a screw placed perpendicular to the proximal femoral physis provides the absolute strongest physeal fixation, this may be mitigated by the risks of a more proximal starting point. Starting the screw distal to the intertrochanteric line, and using a trajectory that is not completely parallel to the physis may provide superior long-term results.

References:

1. Goodwin RC, Mahar AT, Oswald TS, Wenger DR. Screw head impingement after in situ fixation in moderate and severe slipped capital femoral epiphysis. *J Pediatr Orthop.* 2007 Apr-May;27(3):319-25.
2. Gourineni P. Oblique in situ screw fixation of stable slipped capital femoral epiphysis. *J Pediatr Orthop.* 2013 Mar;33(2):135-8.

Question 11

Reduction and fixation of unstable slipped capital femoral epiphysis using the modified Dunn procedure results in:

- 1) a decrease in the rate of avascular necrosis compared to in situ pinning.
- 2) shorter operative time.
- 3) decreased intraoperative blood loss.
- 4) acutely improved anatomic alignment of the proximal femur.
- 5) a decrease in the rate of reoperation.

Preferred Response: 4

Discussion: Unstable slipped capital femoral epiphysis is a challenging problem, with an increased risk of complications compared to stable SCFE, especially the development of avascular necrosis. In an attempt

to minimize the risk of AVN, and to restore normal proximal femoral anatomy, there has been an increase in popularity of the modified Dunn procedure (an open reduction of the SCFE via a surgical hip dislocation with careful preservation of the retinacular vessels) over the past decade. While some preliminary case series showed encouraging results, more recent retrospective case-control studies suggest that the rate of AVN may not be significantly diminished, compared to in situ pinning techniques. The modified Dunn procedure requires increased operative time, and increased blood loss. No significant differences in the ultimate rate of reoperation have been noted. The modified Dunn procedure can restore proximal femoral anatomy better than in situ pinning. Though no long-term studies are available, this may offer the advantage of decreased femoroacetabular impingement or labral damage for patients who do not develop AVN.

References:

1. Souder CD, Bomar JD, Wenger DR. The Role of Capital Realignment Versus In Situ Stabilization for the Treatment of Slipped Capital Femoral Epiphysis. *J Pediatr Orthop.* 2014 Mar;34():
2. Sankar WN, Vanderhave KL, Matheney T, Herrera-Soto JA, Karlen JW. The modified Dunn procedure for unstable slipped capital femoral epiphysis: a multicenter perspective. *J Bone Joint Surg Am.* 2013 Apr 3;95(7):585-91.
3. Tibor LM, Sink EL. Risks and benefits of the modified Dunn approach for treatment of moderate or severe slipped capital femoral epiphysis. *J Pediatr Orthop.* 2013 Jul-Aug;33 Suppl 1:S99-102.
4. Alves C, Steele M, Narayanan

continued on page 14

U, Howard A, Alman B, Wright JG. Open reduction and internal fixation of unstable slipped capital femoral epiphysis by means of surgical dislocation does not decrease the rate of avascular necrosis: a preliminary study. J Child Orthop. 2012 Aug;6(4):277-83.

Question 12

A thirteen year old girl with Down Syndrome has a prolonged history of bilateral spontaneous hip dislocations. While previously this has not been a functional issue, more recently she has shown greater difficulty with ambulation and some "unsteadiness." When younger, she was treated with bracing and therapy without any response. Her hip range of motion is normal. She demonstrates instability with flexion and adduction of the hip.

The most likely primary bony deformity of the hip and its treatment would be:

- A) Acetabular retroversion – treated with a Salter osteotomy
- B) Acetabular retroversion – treated with an Dega osteotomy
- C) Femoral valgus – treated with a varus derotation osteotomy
- D) Acetabular anteversion – treated with a triple osteotomy
- E) Acetabular retroversion – treated with a peri-acetabular osteotomy

E-- is the preferred answer.

Discussion: Patient with Down syndrome and hip instability have been shown to have posterior acetabular deficiency. Treatment addressing this deficiency is based upon appropriate redirection of the acetabulum, achievable with a triple osteotomy or PAO, not with the other osteotomies listed.

References:

1. Sankar WN, Schoenecker JG, Mayfield ME, Kim YJ, Millis MB. Acetabular retroversion in Down syndrome.
2. J Pediatr Orthop. 2012 Apr-May;32(3):277-81. doi: 10.1097/BPO.0b013e31824b27fc.
3. Katz DA, Kim YJ, Millis MB. Periacetabular osteotomy in patients with Down's syndrome.
4. J Bone Joint Surg Br. 2005 Apr;87(4):544-7.

Question 13

15 year old female presents with 3 months of increasing hip pain. You suspect hip impingement based on history and physical exam. All of the following are common in the presentation of this diagnosis except:

- A. History of anterior groin pain
- B. Symptoms exacerbated by long periods of standing
- C. Pain with hip flexion and internal rotation
- D. Decreased hip internal rotation
- E. Commonly present with a "grab sign"

Answer: B

Discussion: Femoroacetabular impingement (FAI) is a common cause of hip pain in the adolescent patient population. The diagnosis can commonly be determined based on history and physical exam. Patients commonly report anterior groin pain that is exacerbated by sitting or sporting activities involving hip flexion. They can present with a "grab sign" – localize pain with their hand with the fingers pointing to the hip and the remainder of the hand reaches toward the great trochanter. In a study by Sink et al, all patients presented with a positive impingement test – pain with hip flexion and internal rotation. Patients

also had decreased hip flexion and limited internal rotation compared to the contralateral side when there was only unilateral FAI.

References:

1. Sink EL, Gralla J, Ryba A, Dayton M. Clinical Presentation of Femoroacetabular Impingement in Adolescents. J Pediatr Orthop. 28: 806-811, 2008.

Question 14

A 6 week old girl is seen in the office for evaluation of hip dysplasia. She was born breech and mom has a history of hip dysplasia and early arthritis. Physical examination shows symmetric thigh folds with negative Ortolani and Barlow tests. Dynamic ultrasound of the hips was performed which showed more than 50% coverage of both femoral heads in the acetabulum and both alpha angles measuring above 60 degrees. What is the next step in the management?

- A) Double diapers for 3 months
- B) Start treatment with Pavlik Harness
- C) No further evaluation is needed; the hip will develop normally
- D) Offer follow up radiographic evaluation of hips at 6 months of age

Answer: D.

The patient has a normal physical examination with a normal ultrasound and may have normal hip development. Breech babies, however, are at very high risk for hip dysplasia, and the dysplasia can develop in the first 6 months even with a normal initial ultrasound so radiographic evaluation at 6 months is recommended by some.

References:

1. J Child Orthop. 2010 Feb;4(1):3-8. doi: 10.1007/s11832-009-0217-2. Epub 2009 Nov 14.

2. Is ultrasound screening for DDH in babies born breech sufficient?
3. Imrie M, Scott V, Stearns P, Bastrom T, Mubarak SJ.

Question 15

A main distinction between the peri-acetabular osteotomy (Ganz) and the triple innominate osteotomy (Steel) is,

- A) The posterior column of the pelvis remains intact with the peri-acetabular osteotomy.
- B) The peri-acetabular osteotomy does not change the diameter of the true pelvis.

C) The peri-acetabular osteotomy allows for greater correction of center edge angle.

D) All of the above

Answer D) All of the above.

When comparing different surgical techniques to address acetabular dysplasia, the peri-acetabular osteotomy is unique in that it maintains the integrity of the posterior column but allows for significant improvement of the center edge angle. Having the posterior column intact allows for earlier weight bearing and easier fixation strategies. Biomechanical studies

have demonstrated an average center edge angle correction of 31 degrees compared to 17 degrees with the triple innominate. The peri-acetabular osteotomy does not change the diameter of the true pelvis and should have no impact on child birth.

References:

1. Maheshwari, R., Osteotomy Techniques and Comparative Effects on Biomechanics of the Hip: A Kinematic Study: Orthopedics December 2011 - Volume 34 · Issue 12: e821-e826

2014 Editorial Board

Robert B. Carrigan, MD
Alice Chu, MD
Steven L. Frick, MD
John J. Grayhack, MD
Christina K. Hardesty, MD
Pooya Hosseinzadeh, MD
Lori A. Karol, MD
Kevin M. Neal, MD
Jon Edward Oda, MD
Kristan A. Pierz, MD - Editor
Brian P. Scannell, MD
James J. Tucci, MD



IPOS 2014 - December 3-6, 2014, Walt Disney World Swan Resort

IPOS 2014 is just around the corner – December 3-6, 2014 at Walt Disney World Swan Resort, Lake Buena Vista, FL: *Michael G. Vitale, MD, MPH and John (Jack) Flynn, MD; Course Directors*

Once again, expect an all-star faculty with numerous concurrent hands on breakout sessions and main sessions including topics such as:

- Trauma – Pearls and Pitfalls
- Essential in Pediatric Orthopaedics
- Ponseti Casting
- Adolescent Idiopathic Scoliosis – State of the Art and Best Practices in 2014
- Upper Extremity Athlete
- Management of Osteomyelitis, Septic Arthritis, and Surgical Infections
- Skeletal Dysplasias / Mucopolysaccharidoses
- The Child's Knee
- "Extreme Surgery": Hope or Hype?
- Pelvic Osteotomies
- Cerebral Palsy
- Improving Safety and the Patient Experience
- Cervical Spine: Trauma and Anomalies
- Child's Upper Extremity: Congenital, Trauma, and Sports
- Challenges in the Office / Practice Management
- Developmental Dysplasia of the Hip
- Issues in the Adolescent Athlete: Lower Extremity
- A special session on "Authors' Preferred Techniques"
- On Call: Urgent Issues
- Building a Sports Practice
- Bone Lesions: From Cysts to Malignancies
- Exotic Spine
- Limb Deformity and Limb Lengthening
- Optimum Multidisciplinary Management of Neuromuscular Disease
- Pediatric Foot: Surgical Management of Congenital and Acquired Conditions
- Adult Consequences of Pediatric Conditions



Check out the IPOS website <http://www.posna.org/ipos/ipos.asp>

We hope to see you all there!

5- How do you see the job market for pediatric orthopedics change as we increase the number of graduates?

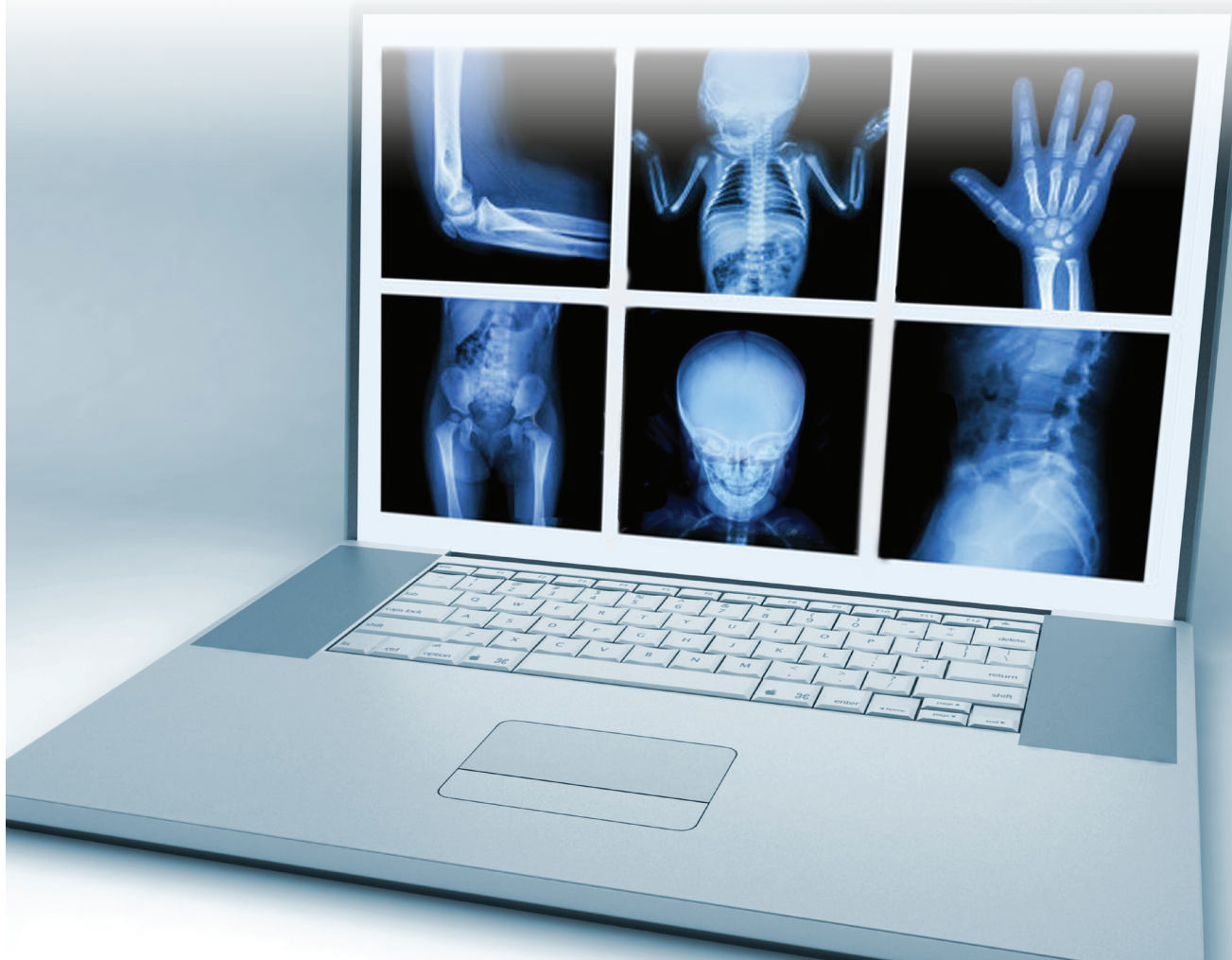This is an ongoing analysis. It really depends on how you define a pediatric orthopaedist. The other issue is that the workforce analysis takes into account large national trends and demand for pediatric orthopaedics may be more local. For example, there are places where there are a large number of pediatric orthopaedic surgeons competing for work (oversupply) and other areas that are probably underserved. There is a mismatch between our surgeon supply and US pediatric population which leads to these differences.

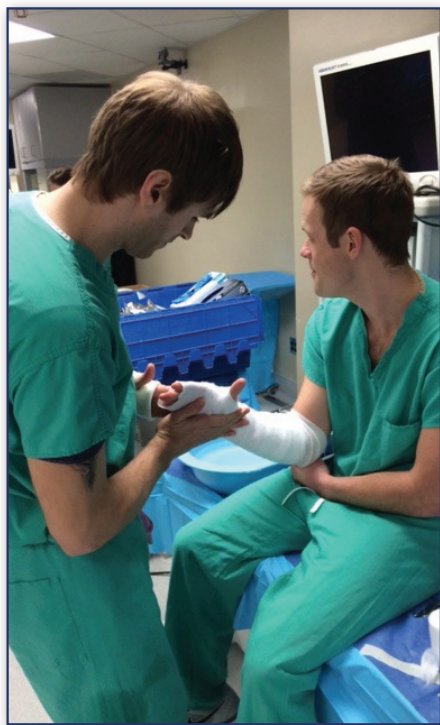6- Could you please briefly describe how you did the work force analysis?

This was done by the Practice Management Committee Board of Directors. It has been a team effort looking at macroeconomic trends such as projected US GDP growth and US pediatric population growth as well as other local factors. We have analyzed the current POSNA membership in terms of age and gender and made projections based on current fellowship trends. We have looked at demand for our services, which is more difficult to do, using the KIDS database as well as surveys of recent graduates of fellowships and AAP members. One key thing is that this workforce analysis needs to

be an ongoing process due to the rapidly changing nature of health care.

These projections are just that, not predictions. A lot of our supply and demand factors are local ones and cannot be determined using large databases. This has been a team effort with a lot of people working very hard on this. —





the barriers mentioned above also need to be addressed to promote widespread adoption. In pediatric orthopedics -- thanks to the commitment of the POSNA leadership to improving education, care, and safety-- the Simulation in Pediatric Orthopaedics Taskforce (SPORT) has been created to address some of these barriers. This multi-center collaborative is working toward developing education curricula, practical simulation models, validated assessment tools, and scientific research protocols to allow for improved simulation training in fundamental pediatric orthopaedic procedures.

Q: What pediatric orthopaedic simulation have you incorporated into the curriculum at your institution?

A: Currently, all residents rotating through Boston Children's Hospital are enrolled in a simulation curriculum in

fundamental pediatric procedures (e.g. distal radius fracture reduction and cast application, supracondylar humerus fracture pinning, in situ fixation of SCFE, and arthroscopic knot tying, etc). This curriculum presents didactic material in the form of articles, lectures, and videos. After reviewing the didactic material, residents perform simulation exercises at the beginning of their rotation. During their rotation, residents are given the opportunity to practice skills on their own time in our simulation facility, and a final assessment is performed at

"...The Simulation in Pediatric Orthopaedics Taskforce (SPORT) has been created to address some of these barriers."

the end of the clinical rotation. Along the way, performance in the simulation exercises is measured with standardized assessment tools as well as video review, and research is being done to correlate simulation training with clinical results and patient safety. Soon additional simulation modules will be rolled out in clubfoot casting and pedicle screw insertion as well.

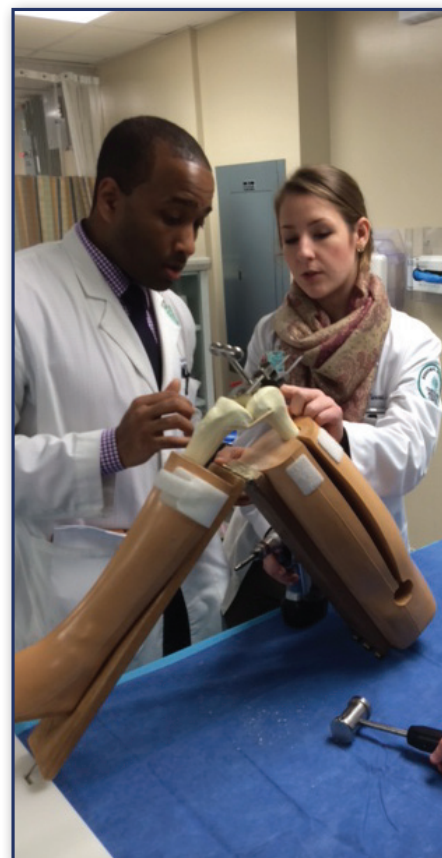Q: How do we objectively evaluate our residents during simulation training?

A: Evaluations should be performed with Objective Standardized Assessments of Technical Skill (OSATS), many of which are currently being developed and validated. These tools may consist of procedural checklists or global rating scales focused on essential steps of each procedure

being evaluated. In addition to these evaluations, providing both real-time and summative feedback is critical for performance improvement.

Q: What do you see as the future role for simulation training in orthopaedics?

A: It is unclear what the future will bring. I do believe that simulation training will become a fundamental part of orthopaedic



education, be it at regional centers or individual institutions. There are also great opportunities to leverage this simulation training to others outside of orthopaedic residency training (medical students, fellows, mid-level providers, etc). The opportunity to improve care, optimize patient safety, and reduce cost is too great to pass up. —

Meetings and Abstract Submission Deadlines

Residents are encouraged to participate in research, and there are many opportunities to present their work. Before submitting an abstract, check with the society's website as some organizations require that presenters be members of the society. Pay attention to details such as whether or not the abstract needs to be "blinded" (authors' names omitted from submission), font, page set up, word count versus character count, conflict of interest statements, deadlines, and other requirements. It is a shame to have an abstract get rejected simply for not following directions. Below is a list of meetings and abstract deadlines for just some of the societies that encourage pediatric orthopaedic submissions. Clearly, there are many other organizations and societies than listed here, but it's a start. Although some deadlines may have already passed for this year, it is never too early to start planning for next year. Meetings are typically held in the same season each year. Check out the organizations' websites for details.

American Academy of Pediatrics (AAP):
October 11-14, 2014 (abstract submission closed
April 11, 2014 – check www.aap.org)

Orthopaedic Trauma Association (OTA):
October 15-18, 2014 (abstract submission
deadline June 23, 2014 – check www.ota.org)

**International Pediatric Orthopaedic
Symposium (IPOS):**
December 3-6, 2014 (eposter submission
deadline October 29, 2014 – check
www.posna.org/ipos/ipos.asp)

**Gait and Clinical Movement Analysis
Society (GCMAS):**
March 17-20, 2015 (abstract submission deadline
October 12, 2014 – check www.gcmas.org)

**American Academy of Orthopaedic Surgery
(AAOS):** March 24-28, 2015 (abstract
submission deadline June 2, 2014)

**Pediatric Orthopaedic Society of
North America (POSNA):**
April 29-May 2, 2015 (abstracts submission deadline
October 8, 2014 – check www.POSNA.com)

Scoliosis Research Society (SRS):
October 21-24, 2015 (abstract submission
date not yet announced - check www.srs.org)

**American Academy of Cerebral Palsy and
Developmental Medicine (AACPDMD):**
October 21-24, 2015 (abstract submission date
not yet announced - check www.aacpdm.org)

**International Limb Lengthening
and Reconstruction Society (LLRS):**
November 4-7, 2015 (abstract submission deadline
coming soon – check www.llrs.org)