



# Resident Review

Cutting Edge Orthopaedic Information Enhancing Resident Education



*Kristan A. Pierz, MD*

## From the Editor

*Kristan A. Pierz, MD*

Welcome to the Fall 2015 issue of Resident Review – a publication designed to educate and inform residents about the field of pediatric orthopaedics. Contributors to this edition are all members of the Pediatric Orthopaedic Society of North America (POSNA).

In this edition, we focus on the spine. In addition to providing a questions and answers section on spine-related topics, we have also included a “Top Picks” annotated reference list. We realize that with so many articles out there, it’s hard to focus your reading. Sometimes you just want to know what the experts think is worth your while, so we’ve included some of our favorite references. Hopefully, you’ll find the articles interesting and informative

Also in this edition, you will find Dr. Pooya Hosseinzadeh’s interview with Dr. Wudbhav Sankar about the fellowship accreditation process. Trying to find the perfect fellowship match can seem like a daunting process. Sifting through lists of programs only to find out that some are and others aren’t “accredited” can be very confusing. Hopefully, this piece will provide you with a better understanding of the process. The world of pediatric orthopaedics is constantly changing, and training needs to keep up with these changes.

To help provide some perspective on the field of pediatric orthopaedics, we have included Dr. Jamie Denning’s interview with Dr. Alvin Crawford, recipient of numerous honors including POSNA’s Distinguished Achievement Award and the American Academy of Orthopaedic Surgeons’ Diversity Award. Dr. Crawford has educated numerous students, residents, and fellows at Cincinnati Children’s Hospital, and his leadership and vision have been truly inspirational.

Finally, the contributing members of Resident Review would like to take this opportunity to acknowledge and thank Dr. Orrin Franko. Dr. Franko recently completed his residency at the University of California, San Diego. As a resident, he was a frequent contributor to Resident Review, hosting “Technology Corner” and keeping us up to date on lots of exciting apps which he still updates on the website [www.TopOrthoApps.com](http://www.TopOrthoApps.com). Although he will be missed, we wish him well in his career and future endeavors.

We truly hope that you find this review helpful and informative. In addition to the content presented here, we refer you to past editions available on the POSNA website [www.posna.org/Blogs/Resident-Review](http://www.posna.org/Blogs/Resident-Review) where you can link to even more articles and study questions. Feel free to share any comments at [kpierz@connecticutchildrens.org](mailto:kpierz@connecticutchildrens.org). ■

## 2015 Editorial Board:

**Lauren Allen, MD**  
Saskatoon, SK Canada

**Robert B. Carrigan, MD**  
Philadelphia, PA

**Jamie Rice Denning, MD**  
Cincinnati, OH

**Steven L. Frick, MD**  
Orlando, FL

**John J. Grayhack, MD**  
Chicago, IL

**Christina K. Hardesty, MD**  
Cleveland, OH

**Pooya Hosseinzadeh, MD**  
Miami, FL

**Meredith Anne Lazar-Antman, MD**  
Garden City, NY

**James McCarthy, MD**  
Cincinnati, OH

**Kevin M. Neal, MD**  
Jacksonville, FL

**Kristan A. Pierz, MD**  
Hartford, CT

**Todd F. Ritzmann, MD**  
Akron, OH

**Jennifer M. Weiss, MD**  
Los Angeles, CA

---

## Update on Fellowship Accreditation: An Interview with Wudbhav Sankar, MD

By Pooya Hosseinzadeh, MD

The fellowship application process can seem confusing and overwhelming. It's important to understand your options and try to pick a program that fits your needs. After residency, fellowships offer the opportunity to subspecialize in an area of particular interest. There are numerous training options available, most of which are administered by the Accreditation Council for Graduate Medical Education (ACGME); however, there is some variability in the system. Resident Review contributor Dr. Pooya Hosseinzadeh recently interviewed Dr. Wudbhav (Woody) Sankar, Chair, Fellowship Training/Qualification for Practice Committee, to help clarify some of the issues facing those looking to train in pediatric orthopaedics.

*Q: We know that some subspecialty fellowships in orthopaedics are moving towards ACGME accreditation. Could you please let us know where POSNA stands when it comes to fellowship accreditation?*

**A:** Some subspecialty societies such as the Orthopaedic Trauma Association (OTA) have recently developed their own accreditation system out of concerns that ACGME was not as relevant to their particular subspecialty. Because of similar concerns, POSNA is considering the development of a POSNA accreditation system. The society is currently working to develop a framework of what this accreditation system might look like and how it could be implemented. This is not necessarily meant to replace ACGME accreditation but to offer an alternative for those fellowship programs that are not ACGME accredited because they think that system is less relevant and too onerous to pursue.

*Q: What efforts have been done in POSNA to address the accreditation issue?*

**A:** The POSNA Fellowship Committee and the Board of Directors is actively working on the concept of a POSNA accreditation system.

*Q: What is your message to future fellowship applicants regarding the accredited and non accredited fellowships? (Should that play a role in choosing the fellowship?)*

**A:** It should be noted that there is no subspecialty certification in pediatric orthopaedic surgery. Right now, many programs have voluntarily sought accreditation through the ACGME, but many excellent fellowship programs have elected not to enter this voluntary process. One goal of a proposed POSNA accreditation system would be to ensure basic standards across all types of pediatric orthopaedic fellowships, but, at this point, I would not advise future fellowship applicants to worry too much about whether or not a fellowship was currently accredited.



Wudbhav Sankar, MD

*Q: In the 2015 Match, the number of unfilled pediatric orthopaedic positions was much higher than in previous years. Do you see that as a new trend?*

**A:** This past year, all 53 North American applicants matched (100%). In 2014, 54 of 57 applicants from North America (95%) matched. Although this number does vary a bit year to year, there are typically 71 pediatric orthopaedic fellowship positions offered across the country. Taken together, the match rate in pediatric orthopaedics for North American applicants remains quite high, and those occasional applicants that do not match most likely would have if they had applied to more programs. Because of changes in requirements for ACGME accreditation, however, it has become somewhat more difficult for foreign medical graduates to match in ACGME accredited pediatric orthopaedic fellowships.

*Q: There is concern among some members that in the past 5 years we have trained too many pediatric orthopaedic surgeons which has decreased the number of available academic jobs. Do you believe that we are training too many pediatric orthopaedic surgeons? Does POSNA plan to address this issue?*

**A:** Opinions on this issue seem to swing back and forth like a pendulum. I remember a few years back when we were concerned as a society that there would be a workforce shortage because of the number of projected retirements of pediatric orthopaedists. Certainly, we have seen a swell in fellowship applicants over the past few years and this has made job searches more competitive. POSNA closely evaluates workforce projections through the practice management committee. Jeff Sawyer and his committee have finished a comprehensive analysis of the pediatric orthopaedic workforce now and for the future. As I understand it, the need continues for more pediatric orthopaedists in many parts of the country, but perhaps not as much for sub-subspecialists in larger urban settings. ■

---

## Alvin Crawford, MD Interview: Changes in Pediatric Orthopaedics During Your Career


Jamie Denning, MD

*Q: The treatment of what condition do you think has changed most dramatically over your career? How?*

**A:** I've noticed that things have a way of being cyclical. Though I never set out to be a spine surgeon; I got "backed into it" back before anyone ever carefully looked at an x-ray from the side. Introduction of the sagittal plane brought a new dimension to the spine for surgeons and, fortunately, patients. Scoliosis and spine surgery are both intriguing and challenging to me. The greatest advances have been the concepts of rod contouring, segmental fixation and selective site spinal fusion. Those patients undergoing "4 to 4" (T4-L4) fusions during my early development may have paid a tremendous price for our education. I've seen and participated in all the iterations of implants from Harrington rods to current segmental stabilization. Routine neuromonitoring is a far-cry from the wake-up test and allows the surgeon to be more creative. Patients are now up and moving around much sooner instead of being bedridden/casted/braced for months. It's amazing and rewarding for me to live and experience this renaissance during my surgical career. This is still a work in progress and I've learned you need a dedicated and at best designated team to make modern spine surgery go smoothly.

*Q: What do you wish had changed more dramatically over your career? Similarly, what do you think will change most dramatically over the next 30 years?*

**A:** SCFE. I thought we had the answer (in situ pinning) but we don't "look" long enough at the patients' outcomes; either you don't live long enough or stay in one location long enough as a surgeon. Follow-up breeds humility. We have a transition team looking at patients in the 18-35 year age group and it's humbling. I'm starting to look at SCFE a little bit differently. We now have a better feel for femoral acetabular impingement and what metaphyseal/articular cartilage/labrum kinematics suffer. The current sophisticated imaging was not available when I was a young on-call surgeon. We now better understand the young adult's pain following less than anatomical in-situ pinning. The hips look (and feel) bad by the time some patients are 25 years old, both the head shape and leg alignment; and even an osteotomy can't fix both. Body mass index certainly plays a roll



Alvin Crawford, MD

---

*“Patients are now up and moving around much sooner instead of being bedridden/casted/braced for months.”*

---

but that's a minor part of the problem. I now realize what the Southwick calculations were trying to tell us years ago. While I haven't been convinced that all need a surgical dislocation anatomical reduction, the Howorth operation equally as big fared well in

longitudinal follow-up, but remains an Ohio operation. I'm frustrated by early onset spine; we haven't found our way yet. Mehta casting is effective when indicated, but I've not been happy with growing rods. The surgical anatomy/physiology doesn't work well for sequential surgical intervention. Moving forward, refinement of implantation not requiring repeated interventions and development of dependable vertebral growth modulation approaches will better serve this population.

*Q: How has the diversity of pediatric orthopaedic staff changed? What more should we be doing?*

**A:** I feel comfortable saying that we had one of the first truly diverse faculty at Cincinnati Children's Hospital. From 1977-2005, there wasn't another person "who looks like me" directing a pediatric orthopaedic service. I think it is valuable to have faculty that are underrepresented minorities because the patients that come in through our ED (urban, largely black, often immigrant population surrounds our hospital) often look different than elective practice patients (suburban, more white population) and they appreciate having someone with whom they can identify. There's been an increase in women in pediatric orthopaedics and attitudes have changed over the past 30 years also. Congratulations to our POSNA president. I like to show a surgical case photo taken years ago of members of our group depicting a "testosterone free spine surgical team" of women which included ethnic minorities. There is a lot of room in pediatric

*continued on page 4*

orthopaedics for staff that are underrepresented minorities. My experience is that most often children are mostly free of entrenched feelings about their care givers and love you if you can get them back to playing with their friends regardless of how you look...sometimes in spite of the parents attitudes. It's one of the more satisfying characteristics of our profession. Diversity brings lots of unique ideas to the specialty. More centers should consider it in mentoring medical students/residents and recruiting.

**Q:** *What is your take on the shift from "generalization" to "sub specialization"?*

**A:** Even though you can define sub-specialization as "knowing more and more about less and less," sub-specialization is good for the humans we treat. I was initially attracted to pediatric orthopaedics because it allowed me to be a comprehensive musculoskeletal surgeon for the skeletally immature. Those days are over and may be timely because through molecular genetics we know so much more about some of the conditions we treat and it would be impossible for one discipline to stay current and resourceful for all of our patient's needs. Instead of the current system of sub-specialization which focuses more on one body part within pediatric orthopaedics, I would love to see a more European system where surgeons treat a body part not necessarily "birth to the grave" but from the newborn to at least into early adulthood. We haven't been training that way, but I can imagine future

pediatric orthopaedic fellowships including something of a young adult transition clinic which could potentially be integrated with an adult program. I can envision providers being attracted to this continuity concept.

**Q:** *Any words to live by to enjoy a wonderful career in pediatric orthopaedics? (In Cincinnati, and all over the world where there are Crawford disciples, these pearls are referred to as "Crawfordisms")*

**A:** "You really have to care."

"The patient shouldn't pay dearly for your education."

"God only gives the hip one head per life per child."

"God is good to the Pediatric Orthopaedist: you're given growth (plate) and development to assist you in some short comings."

"Cherish failure to teach you how to better care for the next child."

"You may be the most consistent care provider throughout the patient's entire childhood."

"Our specialty loves you; you have to love it; and at the end of the day, that's worth more than your check." ■

## 12th Annual International Pediatric Orthopaedic Symposium (IPOS)

Looking for a great way to acquire some knowledge, practice some skills, and enjoy a little fun in the sun? Check out the 12th Annual International Pediatric Orthopaedic Symposium, December 8-12, 2015 in Orlando, Florida. Presented by POSNA and AAOS, IPOS showcases evidence-based techniques and research, hands-on practice, and emerging issues across the spectrum of pediatric and adolescent orthopaedic care. Come early and enjoy a special resident session on Tuesday, December 8.

For more information, go to <http://ipos.posna.org> ■



## Top Picks

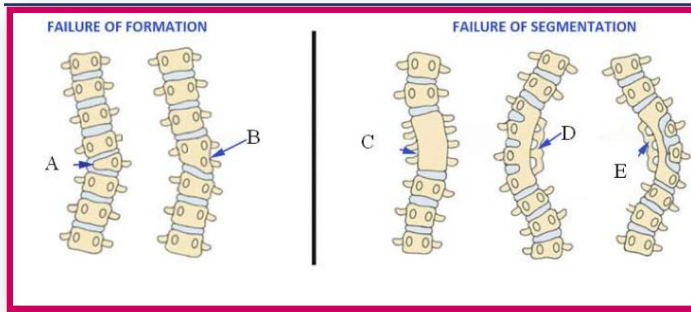
Looking for something to read? Overwhelmed with all of the literature that's out there? Wondering what articles are worth looking at? Well, here are some suggestions. Since this edition of Resident Review focuses on spine issues, we picked some of our favorite spine related articles. Here are our "top picks" along with a brief explanation about why each one made it to the list. Hopefully, you will find these articles interesting, informative, and, who knows, maybe they'll even help you on your upcoming OITE.

- 1. Weinstein SL: Natural History. Spine 1999. Dec 15;24(24):2592-600.**  
*Excellent summary of literature regarding the natural history of scoliosis, and serves as an invaluable tool for the pediatric orthopaedic surgeon making treatment recommendations and discussing these with patients and families.*
- 2. Sturm PF, Anadio JM, Dede, O: Recent Advances in the Management of Early Onset Scoliosis. Orthopedic Clinics of North America Volume 45, Issue 4, October 2014, pp 501-514.**  
*For a non-spine peds person, this is an excellent article to give an overview of early onset scoliosis. There have been a lot of recent developments in EOS, and this covers them and has an excellent list of reference articles to refer to for more detail.*
- 3. SL Weinstein, LA Dolan, JG Wright, MB Dobbs: Effects of bracing in adolescents with idiopathic scoliosis. New England Journal of Medicine Oct 2013; 369:1512-1521.**  
*A recent favorite spine article is the BrAIST study. This is a multicenter study that set out to definitely answer an important question--does treatment with a TLSO prevent the progression of idiopathic adolescent scoliosis? It's simplified the bracing discussion that I have with families and I think the results have motivated a lot of my patients.*
- 4. Thompson GH1, Akbarnia BA, Kostial P, Poe-Kochert C, Armstrong DG, Roh J, Lowe R, Asher MA, Marks DS: Comparison of single and dual growing rod techniques followed through definitive surgery: a preliminary study. Spine (Phila Pa 1976). 2005 Sep 15;30(18):2039-44.**  
*This was a well-done multicenter study which changed the way many people treated early onset scoliosis. It is frequently referenced and should be read by anyone who treats early onset scoliosis, as it highlights the principles behind "driving" the spine and controlling correction in multiple planes.*
- 5. Sanders JO, Newton PO, Browne RH, Katz DE, Birch JG, Herring JA. Bracing for idiopathic scoliosis: How many patients require treatment to prevent one surgery? J Bone Joint Surg Am. 2014 Apr 16;96(8):649-53.**  
*This 2014 JBJS article by Sanders, et al. provides an excellent analysis of the same data used in the scoliosis brace compliance study with temperature sensors from Katz, et al. in 2010. Sanders, et al. calculate a number needed to treat (NNT) of 3, indicating that we are likely changing the natural history of scoliosis for 1 of every 3 patients for whom we prescribe a brace using standard Scoliosis Research Society (SRS) criteria. While the study confirms that bracing is effective for some, it also shows that we brace too many patients unnecessarily. Expect this study, along with the BrAIST study, which also determined a NNT between 3 and 4, to be touchstones as we refine bracing criteria for AIS in the future.*

## Practice Questions:

With the Orthopaedic In-Training Exam (OITE) just around the corner, it's a good time to brush up and do a little review. In this edition, we offer some spine-related questions to test your knowledge and help you prepare.

### Question 1



Of the patterns shown above, which is the most benign pattern and least likely to require surgery?

- A) A
- B) B
- C) C
- D) D
- E) E

*Preferred answer: C*

**Discussion:** Block vertebra, a bilateral failure of segmentation, tends to be the most benign anomaly; the most severe and progressive deformity usually is the unilateral bar with contralateral hemivertebra, which may progress up to 10° per year in the thoracolumbar region. Progression occurs during the first 3 years of life, then again during adolescent growth spurts. The rate of progression, from greatest to least is unilateral unsegmented bar with contralateral hemivertebra, unilateral unsegmented bar, fully segmented hemivertebra, unsegmented hemivertebra, incarcerated hemivertebra, unincarcerated hemivertebra, and block vertebrae.

#### References:

- Hedequist D, Emans J. Congenital scoliosis. *J Am Acad Orthop Surg.* 2004 Jul-Aug;12(4):266-75.
- Holte DC, Winter RB, Lonstein JE, Denis F. Excision of hemivertebrae and wedge resection in the treatment of congenital scoliosis. *J Bone Joint Surg Am.* 1995 Feb;77(2):159-71.

### Question 2

A 7 year old boy presents to your office with fixed torticollis. His mother reports that it has been present for 5 days following a minor fall while playing at school. He has no history of recent fever, illness, or upper respiratory tract infection. Cervical spine X-Rays in your office are suggestive of torticollis, but show no fractures or congenital abnormalities. The most appropriate next step is to:

- A) Place a cervical collar and recommend anti-inflammatory medication.
- B) Obtain a dynamic CT scan of the atlantoaxial joint.
- C) Admit the patient to the hospital for halter traction and muscle relaxers.
- D) Admit the patient to the hospital to place skeletal traction, followed by a halo vest.

*Preferred answer: A*

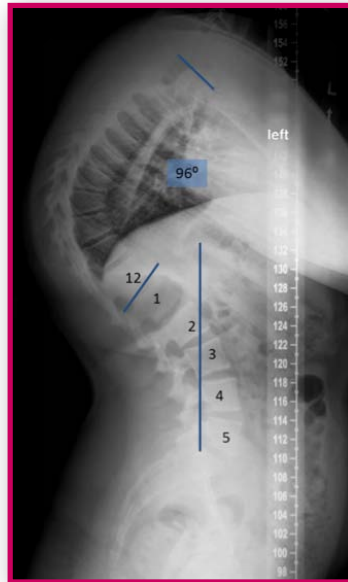
**Discussion:** Atlantoaxial rotary subluxation (AARS) is defined as an acute, fixed torticollis of the cervical spine. AARS may be spontaneous, or may be preceded by minor trauma. Some cases are related to inflammation induced by infection of the neck region. In this patient, no recent fever, illness, or URI argues against infection as a cause. Radiographs are useful to exclude obvious trauma and congenital abnormalities, but may be difficult to interpret due to the tilted position of the head. The diagnosis of AARS should be made primarily by the history and physical exam. Subluxation of the C1-2 articulation is a given in a patient with a fixed torticollis. Advanced imaging adds little to the diagnosis or management in acute cases. CT scans of the neck also have the undesirable risks associated with ionizing radiation in children. For acute AARS (presenting 2 weeks or less from onset), supportive measures such as a cervical collar and anti-inflammatory medication are the most appropriate initial treatment. Most cases will resolve with these measures alone. Initiating cervical halter traction and benzodiazepines is appropriate for cases presenting more than 2 weeks from the onset of symptoms, as they have a higher failure rate with simple measures. Skeletal traction, halo vest immobilization, and C1-2 fusion are reserved for recalcitrant cases.

#### References:

- Orthopaedic Knowledge Update 8.* Alexander R. Vaccaro (Editor). Published by American Academy of Orthopaedic Surgeons, Rosemont, IL. Copyright 2005.
- Hedequist D, Emans J. Congenital scoliosis. *J Am Acad Orthop Surg.* 2004 Jul-Aug;12(4):266-75.
- Kawakami N, Tsuji T, Yanagida H et al. Radiographic analysis of the progression of congenital scoliosis with rib anomalies during the growth period. *ArgoSpine News & Journal.* 2012 Jun; 24(1): 56-61.

### Question 3

A 16 year old male presents with complaints of isolated activity related mid back pain and worsening posture. Clinical examination reveals thoracic hyperkyphosis without an acute gibbus with moderate flexibility on hyperextension testing. Neurologic examination is normal. Radiographs reveal a 94 degree thoracic kyphosis. Treatment recommendations should include:



- A) Posterior spinal fusion from T2-T12 with multiple Ponte osteotomies and pedicle screw instrumentation
- B) Combined anterior / posterior spinal fusion from T2-L1 with pedicle screw instrumentation
- C) CTLSO extension bracing and physical therapy for core and paraspinal strengthening
- D) Posterior spinal fusion from T2-L2 with multiple Ponte osteotomies and pedicle screw instrumentation.
- E) T9 Pedicle subtraction osteotomy and T2-L1 posterior spinal fusion with pedicle screw instrumentation

*Preferred answer: D*

**Discussion:** Surgery for Scheuermann's kyphosis, characterized by vertebral wedging and progressive deformity, is considered for kyphosis exceeding 75 degrees, pain, and neurologic compromise. Improved pedicle screw fixation and osteotomies have decreased need for anterior releases. Fusion levels should include the entire kyphotic Cobb angle and stop distal to the first lordotic disc.

#### References:

1. Cho KJ, Lenke LG, et al. Selection of the Optimal Distal Fusion Level in Posterior Instrumentation and Fusion for Thoracic Hyperkyphosis. *Spine* 2009. 34(8):765-770.
2. Lundine K, Turner P, Johnson M. Thoracic hyperkyphosis: assessment of distal fusion level. *Global Spine J*. 2012. 2(2):65-70.
3. Geck MJ, Macagno A, Ponte A, Shufflebarger HL. The Ponte procedure: posterior only treatment of Scheuermann's kyphosis using segmental posterior shortening and pedicle screw instrumentation. *J Spinal Disord Tech*. 2007. 20(8):586-93.

### Question 4

The risk of curve progression for adolescent idiopathic scoliosis has been most-closely associated with peak height velocity, during which there is a "curve acceleration phase". Which objective marker is the most accurate for determining the curve acceleration phase for patients with idiopathic scoliosis?

- A) Risser sign
- B) Tanner stage
- C) Serum estrogen levels
- D) Closure of epiphyses in the hand

*Preferred answer: D*

**Discussion:** Predicting the natural history of idiopathic scoliosis necessitates an assessment of current curve size and remaining growth. The most commonly used markers for remaining growth include Risser staging on a PA scoliosis radiograph, and assessment of hormonal development by determining the age at menarche for girls. Recently, there has been renewed interest in establishing a more accurate method to determine when curves are most likely to progress. In 2008, Sanders, et al. published a simplification of the Tanner-Whitehouse-III RUS system for determining bone age with a left wrist radiograph. The Tanner-Whitehouse-III RUS (radius-ulna-small bones of the hand) system relies on assessment of the phalangeal and metacarpal epiphyses, as well as the distal radius. In a previous study, Sanders determined that the Tanner-Whitehouse-III system correlated best with the curve acceleration phase, and was more accurate than Risser staging, Tanner staging, and serologic studies. In the 2008 study, Sanders provides a table based on the curve size and the simplified classification that stratifies the risk of a curve progressing to >50 degrees (and therefore possibly requiring surgery).

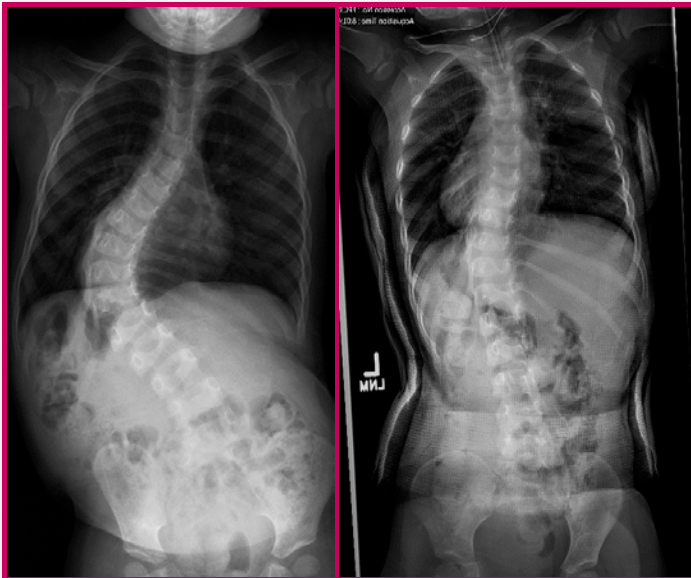
#### References:

1. Sanders JO, Browne RH, McConnell SJ, Margraf SA, Cooney TE, Finegold DN. Maturity assessment and curve progression in girls with idiopathic scoliosis. *J Bone Joint Surg Am*. 2007 Jan;89(1):64-73.
2. Sanders JO, Khoury JG, Kishan S, Browne RH, Mooney JF 3rd, Arnold KD, McConnell SJ, Bauman JA, Finegold DN. Predicting scoliosis progression from skeletal maturity: a simplified classification during adolescence. *J Bone Joint Surg Am*. 2008 Mar;90(3):540-53.

*continued on page 8*

### Question 5

A 28 month old female with an infantile idiopathic scoliosis of 86 degrees magnitude and RVAD of 35 degrees has initiation of serial Mehta casting with first in cast correction to 31 degrees as shown. Parents should be advised the following regarding prognosis and potential future treatment.



- A) Serial casting should be aborted with transition to Boston brace therapy.
- B) Serial casting should be continued with anticipation of curve resolution after 12 months of treatment.
- C) Serial casting should be continued with anticipation of transition to Boston brace after 12 months of treatment and successful delay in initiation of surgical intervention.
- D) Serial casting should be aborted with transition to growing-rod therapy.
- E) Serial casting should be aborted with transition to VEPTR therapy.

Preferred answer: C

**Discussion:** Infantile idiopathic scoliosis presents prior to age 3 years, is more common in boys than girls, and often involves a left thoracic curve. Mehta serial casting is recommended for flexible curves > 25-30 degrees with a rib vertebral angle difference (RVAD) > 20 degrees. Following casting, bracing is recommended to maintain a corrected RVAD of zero for many months or to delay definitive surgery if necessary. Growing rods or VEPTR techniques are now available for curves that fail to correct or that continue to progress despite casting or bracing.

### References:

1. Sanders JO, D'Astous J, et al. Derotational casting for progressive infantile scoliosis. *J Pediatr Orthop.* 2009. 29(6):581-7.
2. Fletcher ND, McClung A, et al. Serial casting as a delay tactic in the treatment of moderate-to-severe early-onset scoliosis. *J Pediatr Orthop.* 2012. 32(7):664-71.
3. Mehta MH. Growth as a corrective force in the early treatment of progressive infantile scoliosis. *J Bone Joint Surg Br.* 2005. 87:1237-1247.

### Question 6

A 13 year old male presents to the office complaining of back pain. He recalls feeling a pop in his back several weeks ago at wrestling practice and has felt tightness ever since and unable to participate. He complains of pain radiating down bilateral lower extremities. On physical exam he has pain with straight leg raise on the right side and no pain with straight leg raise on the left. The remainder of the physical exam is normal. X-ray reveals minimal scoliosis; MRI demonstrates disc herniation at L5-S1. What is the next step in management?

- A) Surgery for disc extrusion
- B) Activity modification, physical therapy, and NSAIDs
- C) Bone scan
- D) CT scan
- E) Thoraco-lumbo-sacral orthosis (TLSO)

Preferred answer: D

**Discussion:** The patient clearly has a herniated disc on MRI findings. His x-ray demonstrates a reactive scoliosis which is not uncommon in pediatric herniated discs. The acute onset of pain followed by no relief over a period of several weeks is typical of a pediatric disc herniation. While activity modification, PT, and NSAIDs may be appropriate, these types of injuries can be associated with the ring apophyseal fractures which can be seen on CT scan. While this may not necessarily change the treatment, an appropriate diagnostic work-up should be performed. A CT scan would also allow you to rule out a spondylolysis as well.

### References:

1. Lavelle WF, Bianco A, Mason R, Betz RR, Albanese SA. Pediatric disk herniation. *J Am Acad Orthop Surg.* 2011 Nov;19(11):649-56. Review.



### Question 7

Which of the following is true regarding congenital scoliosis?

- A) The pattern of congenital scoliosis most likely to progress is a unilateral unsegmented bar with contralateral hemivertebra.
- B) There is not generally a need to screen for associated cardiac or renal anomalies because the association with congenital scoliosis is rare.
- C) The pattern of congenital scoliosis most likely to progress is a block vertebra.
- D) The most rapid progression of congenital scoliosis happens just before onset of puberty.
- E) The presence of fused ribs along with congenital scoliosis usually decreases the risk of progression.

Preferred answer: A

#### Discussion:

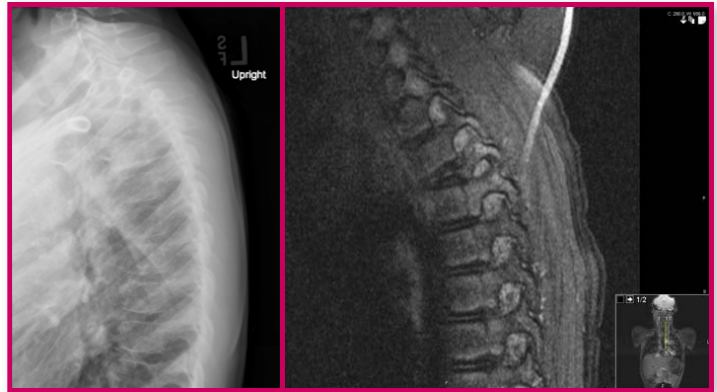
- A) **TRUE** – This pattern is most likely to progress rapidly at 5-10 degrees per year.
- B) **FALSE** – there is a high rate of associated anomalies with congenital scoliosis [~60%] generally in body systems that also develop around 4-6 weeks gestational age: cardiac anomalies in 10% and genitourinary anomalies in 25%. An echocardiogram +/- renal ultrasound is recommended screening once congenital scoliosis is recognized.
- C) **FALSE** – a block vertebra has the least chance of progression, usually <2 degrees per year.
- D) **FALSE** – progression of congenital scoliosis is most rapid in the first 3 years of life
- E) **FALSE** – the presence of fused ribs usually increases the risk of progression.

#### References:

1. *Orthopaedic Knowledge Update 8*. Alexander R. Vaccaro (Editor). Published by American Academy of Orthopaedic Surgeons, Rosemont, IL. Copyright 2005.
2. Hedequist D, Emans J. Congenital scoliosis. *J Am Acad Orthop Surg*. 2004 Jul-Aug;12(4):266-75.
3. Kawakami N, Tsuji T, Yanagida H et al. Radiographic analysis of the progression of congenital scoliosis with rib anomalies during the growth period. *ArgoSpine News & Journal*. 2012 Jun; 24(1): 56-61.

### Question 8

An 11 yo otherwise healthy female presents with a history of mild persistent back pain over the last 4 months. She has had no trauma or injury. At this time she denies any weakness or numbness in her upper extremities. Her reflexes and strength are normal and there are no signs of torticollis. The pain does not wake her at night. There is no family history of spinal deformity. There are no other findings on skeletal survey. X-ray and MRI are shown. What is the next most appropriate step in management?



- A) Observation
- B) Biopsy
- C) Posterior in situ spinal fusion
- D) Anterior vertebroplasty
- E) Posterior fusion with instrumentation

Preferred answer: A

**Discussion:** Vertebra plana is a common finding in eosinophilic granuloma and solitary lesions can be treated with observation alone in absence of neurologic deficits. With healing, a varying degree of vertebral height can be restored in these lesions. Occasionally, when a question about the diagnosis arises, a biopsy can be performed. Bracing can also be considered, although there is no guarantee of effectiveness in pain relief.

#### References:

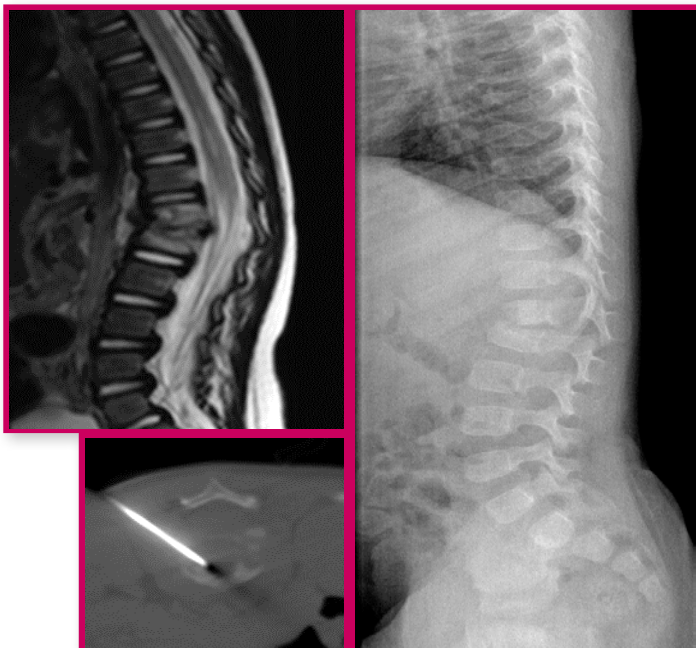
1. Tracy T Jr, Neifeld JP, DeMay RM, et al. Malignant fibrous histiocytomas in children. *J Pediatr Surg*. 1984; 19:81.
2. Denaro, Luca, Longo, Umile Giuseppe, Papalia, Rocco, et al. Eosinophilic Granuloma of the Pediatric Cervical Spine. *Spine*. 2008 Nov 15;33(24):E936-4.

continued on page 10

### Question 9

11 month old male who recently started ambulating presents to emergency room after refusing to ambulate and reverting back to crawling. No history of trauma was noted and patient was afebrile. Exaggerated thoracolumbar kyphosis was noted on physical examination. WBC, differential, and C-reactive protein are normal. ESR mildly elevated at 25. Radiographs and MRI demonstrated in figures. Transpedicular vertebral biopsy is culture negative, AFB negative and histology demonstrates acute and chronic inflammation. What is the most likely diagnosis and what is the recommended treatment for this patient?

- A) Langerhans cell histiocytosis of the spine - transpedicular corticosteroid injection.
- B) Ewings cell sarcoma – neoadjuvant chemotherapy followed by en bloc resection and instrumented fusion
- C) Pott’s disease / spinal TB – antituberculosis medication and extension TLSO bracing
- D) Vertebral compression fracture – Risser extension casting for 6 weeks followed by extension TLSO bracing
- E) Infectious spondylolysis/discitis – 6 weeks antibiotic therapy and extension TLSO bracing



Preferred answer: E

**Discussion:** Pediatric discitis/spondylolitis (disc space infection) is more common in pediatric patients (especially under 5 years) than adults. Staph aureus is the most common organism (> 80%) and empiric antibiotics to

cover this should be used if culture fails to confirm bacteria. Fever is only seen in approximately 25%, and inflammatory labs may be normal or only mildly elevated. In this case, biopsy was consistent with acute and chronic inflammation, making discitis the most likely diagnosis.

#### References:

1. Crawford AH, Kucharzyk DW, et al. Diskitis in children. *Clin Orthop Relat Res.* 1991. 266:70.
2. Spencer SJ, Wilson NI. Childhood discitis in a regional children’s hospital. *J Pediatr Orthop B.* 2012. 21(3):264-8.
3. Ring D, Johnston, Wenger DR. Pyogenic infectious spondylolitis in children: the convergence of discitis and vertebral osteomyelitis. *J Pediatr Orthop.* 1995. 15:652.

### Question 10

Which of the following statements regarding spondylolisthesis is true?

- A) Low grade slips are associated with spinopelvic imbalance.
- B) Pelvic incidence = Sacral slope – Pelvic tilt.
- C) High grade slips can be further sub-classified based on their sacropelvic and spinopelvic balance.
- D) High grade slips with a pelvic tilt > 30° likely have a balanced pelvis.
- E) The Spinal Deformity Study Group (SDSG) classification divides L5-S1 spondylolisthesis into 8 types.

Preferred answer: C

**Discussion:** The Spinal Deformity Study Group (SDSG) classification for L5-S1 spondylolisthesis consists of 6 types. In that classification, high grade slips are sub-classified based on their sacropelvic and spinopelvic balance. High grade slips with a larger pelvic tilt (i.e. > 30°) are more likely to have sacropelvic unbalance, while low grade slips generally have spinopelvic balance. Pelvic incidence is a radiographic parameter that describes a subject’s pelvic anatomy. It is constant within an individual and is the sum of sacral slope and pelvic tilt.

#### References:

1. Reliability and development of a new classification of lumbosacral spondylolisthesis. Mac-Thiong JM, Labelle H, Parent S, Hresko T, Deviren V, Weidenbaum M, members of the Spinal Deformity Study Group. *Scoliosis* 2008; 3: 19.
2. The importance of spino-pelvic balance in L5-S1 developmental spondylolisthesis. A review of pertinent radiologic measurements. Labelle H, Roussouly P, Berthonnaud E, Dimnet J, O’Brien M. *Spine* 2005; 30(6S): S27.

### Question 11

Which of the following statements regarding bracing in adolescent idiopathic scoliosis (AIS) is false?

- A) There is evidence of a strong dose-response effect in bracing for AIS.
- B) BrAIST results confirm that curves will progress significantly if untreated.
- C) The number needed to treat in order to prevent one surgery likely falls somewhere between 3 and 9, depending on compliance.
- D) Brace wear for less than 6 hours per day seems to have a similar effect to observation alone.
- E) Common indications for bracing AIS include an adolescent with an idiopathic curve between 20° and 40°, and a Risser 0, 1 or 2 status.

Preferred answer: B

**Discussion:** Some, but not all, curves will progress significantly if untreated. In the BrAIST article, treatment success (Cobb <50° at skeletal maturity) was encountered in 75% of braced patients and 42% of observed patients. Thus, some untreated patients failed to progress significantly, despite lack of treatment. BrAIST also showed evidence of a strong dose-response effect in bracing for AIS and that brace wear for less than 6 hours per day seems to have a similar effect to observation alone. Common indications for bracing in AIS include an adolescent with an idiopathic curve between 20° and 40°, and a Risser 0, 1 or 2 status. These criteria were used in the aforementioned study. The number needed to treat in order to prevent one surgery likely falls somewhere between 3 and 9, depending on patient compliance.

#### References:

1. *Effects of bracing in adolescents with idiopathic scoliosis.* Weinstein SL, Dolan LA, Wright JG, Dobbs MB. *N Engl J Med.* 2013 Oct 17;369(16):1512-21.
2. *Bracing for idiopathic scoliosis: how many patients require treatment to prevent one surgery?* Sanders JO, Newton PO, Browne RH, Katz DE, Birch JG, Herring JA. *J Bone Joint Surg Am.* 2014 Apr 16;96(8):649-53.
3. *Bracing in adolescent idiopathic scoliosis, surrogate outcomes, and the number needed to treat.* Sanders JO, Newton PO, Browne RH, Herring AJ. *J Pediatr Orthop.* 2012 Sep; 32 Suppl 2:S153-7.

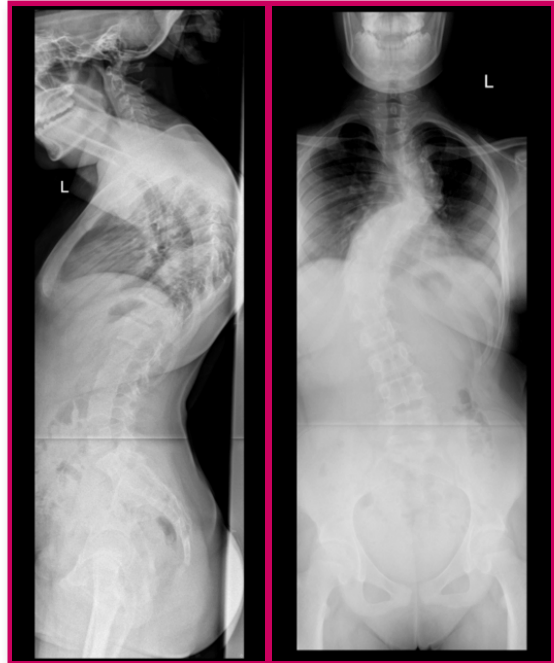
### Question 12

Which of the following statements is most likely false in this patient?

- A) This curve could be associated with axillary freckling.
- B) This curve, if treated surgically, could be at higher risk of nonunion.

- C) This deformity could be associated with dural ectasia.
- D) This deformity has a low chance of responding to bracing.
- E) Most patients with this type of curve also have congenital pseudarthrosis of the tibia (CPT).

Preferred answer: E



**Discussion:** Roughly 75% of patients with congenital pseudarthrosis of the tibia (CPT) have neurofibromatosis but only about 5% of patients with neurofibromatosis also have CPT. The short, sharp kyphoscoliosis shown in this picture could be associated with neurofibromatosis (NF), which can also be associated with café-au-lait macules, axillary and inguinal freckling, iris (Lisch) nodules, optic gliomas, neurofibromas, elephantiasis, pseudarthrosis of the tibia, gigantism, hemihypertrophy, dystrophic vertebrae or ribs. Dystrophic changes include vertebral scalloping, rib penciling, transverse process spindling, vertebral wedging, paravertebral soft-tissue mass, a short curve with severe apical rotation, intervertebral foraminal enlargement, widened interpediculate distances, dysplastic pedicles and dural ectasia.

Such a curve has a lower chance of responding to bracing, given the curve is >40°, kyphotic and may have some other dysplastic features (which could be further evaluated with MRI and CT). It is at risk of non-union if treated surgically.

#### References:

1. *Orthopaedic manifestations of neurofibromatosis type 1.* Feldman DS, Jordan C, Fonseca L. *J Am Acad Orthop surg.* 2010 Jun;18(6):346-57.